



## A Short Recurrence Time of Left Atrial Myxoma: Case Report and Literature Review

Kawtar Manouri<sup>1</sup>, Jihad Raoui, MD<sup>2</sup>, Hicham Wazaren, MD<sup>3</sup>, Siham El Hallab, MD<sup>4</sup>, Nawal Doghmi, Ph.D<sup>5</sup>

<sup>1,2,4,5</sup> Cardiologist, Department of Cardiology B, IBN SINA HOSPITAL CENTER, Rabat, Morocco

<sup>3</sup> CT surgeon Department of Cardiovascular Surgery A, IBN SINA HOSPITAL CENTER, Rabat, Morocco

ARTICLE INFO	ABSTRACT
Published Online: 15 January 2021	<b>Background:</b> Recurrence of sporadic cardiac myxoma remains unusual but the seriousness of the situation justifies the realization of a surgical resection as complete as possible with post-operative clinical and echocardiographic monitoring. <b>Case presentation:</b> We recall the case of myxoma of the left atrium in a 64-year-old women complicated by functional mitral stenosis and heart failure. She underwent urgent heart surgery, during which a friable tumor attached by a sessile base to the anterior atrial septum was removed. The postoperative effects were complicated by a pulmonary embolism. Eight months later, the patient consulted for exertional dyspnea with an echocardiographic image in favor of a recurrence of myxoma of the left atrium.
Corresponding Author: <b>Kawtar Manouri</b>	<b>Conclusion:</b> Several mechanisms have been proposed to explain such recurrence, the most avoidable remain incomplete surgical resection and Implantation of embolic fragments of the original tumor in the myocardium due to a previous surgery.
<b>KEYWORDS:</b> Atrial myxoma; recurrence; echocardiogram; left atrium.	

### Abbreviated legend for your Central Picture

TEE: trabsthoracic echocardiography

TEO: transoesophageal echocardiography

### INTRODUCTION

Cardiac myxoma is a benign neoplasm that performs a tissue excrescence from the most localized embryonic mesenchymal remnants often at the interatrial septum.

There is a contrast between the benign nature of the tumour and the cardiac and extracardiac complications that it can engender.

Recurrence of intracardiac myxoma is unusual, sporadic cases have a very low recurrence rate of 1%-3 % (1).

This article reports a case of left atrial myxoma primarily presenting with heart failure by mitral stenosis with a recurrence 8 months after complete surgical excision.

### CASE HISTORY

We report a case of 64-year-old women without modifiable cardiovascular risk factors. From her medical history we learned a pleural tuberculosis treated and declared cured in

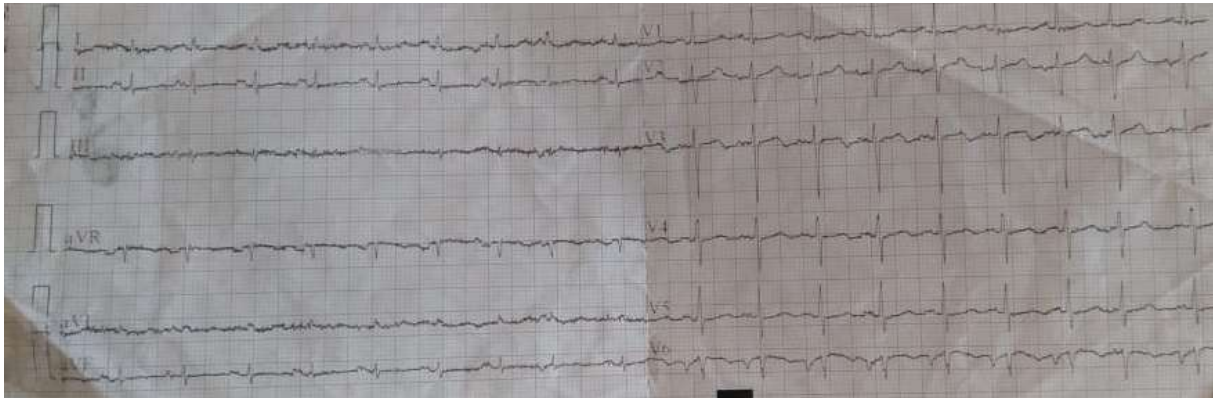
1981. Patient's history was negative for occurrence of cardiac tumors in the family.

In March 2020 the patient presented to the emergency room with congestive heart failure.

On admission, she had the symptoms of orthopnea, chest discomfort and paroxysmal nocturnal dyspnea, which she said started 2 months earlier, but had suddenly worsened over the last week.

On physical examination, her blood pressure was 105/63 mmHg, heart rate of approximately 98 bpm. She had a polypnoea, oxygen saturation as measured by pulse oximetry [SpO<sub>2</sub>] was 95% , with signs of congestive heart failure, a loud S1 and diastolic murmur at the mitral focus with pulmonary S2 duplication.

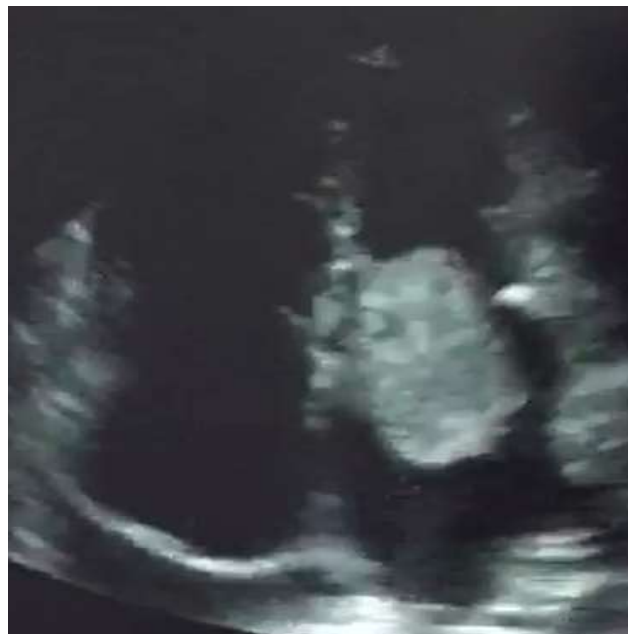The electrocardiogram (ECG) records sinus tachycardia with left atrial overload (fig 1).



**Figure 1:** ECG records sinus tachycardia with left atrial hypertrophy.

Two-dimensional trans-thoracic echocardiography (TEE) revealed a vague echogenic mobile mass in the left atrium with attachment to the atrial septum, prolapsing into the left ventricle, causing functional mitral valve stenosis (**fig 2**).

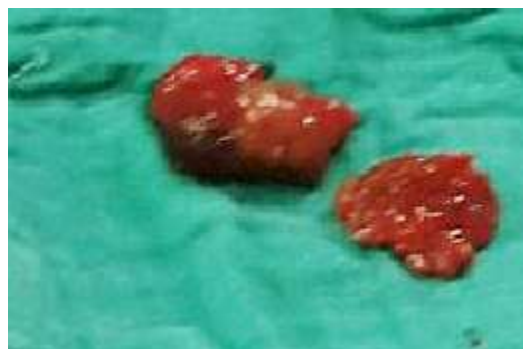Biauricular, right ventricular and tricuspid valve annulus dilatation with pulmonary arterial hypertension were also noted. The pericardium was the site of minimal effusion. The left ventricular ejection fraction was 52%.



**Figure 2:** TEE revealed an echogenic mobile mass in the left atrium with attachment to the atrial septum, prolapsing into the left ventricle, causing functional mitral valve stenosis.

Laboratory investigations at the time of diagnosis yielded the following results: HGB: 12.2 g/dl, WBC: 10930 / mm<sup>3</sup>, PLT: 355000 /mm<sup>3</sup>, Urea: 0.48 g/l, Creatinine: 9 mg/l, C-Reactive Protein: 110 mg/l, Na<sup>+</sup>: 139 mEq/l, K<sup>+</sup>: 3.6 mEq/l; TP: 55%.

She underwent urgent heart surgery, during which a friable tumor attached by a sessile base to the anterior atrial septum was removed (**fig3**). The mitral valve was healthy and a tricuspid annuloplasty was put in place.

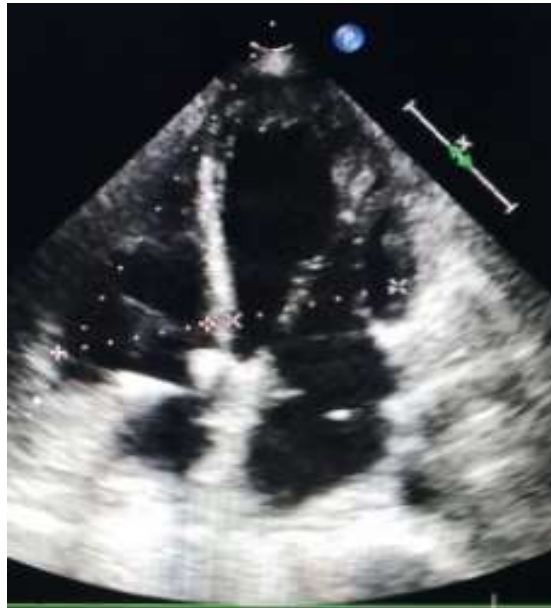

**Figure3:** Macroscopic appearance of surgical specimen.

## “A Short Recurrence Time of Left Atrial Myxoma: Case Report and Literature Review”

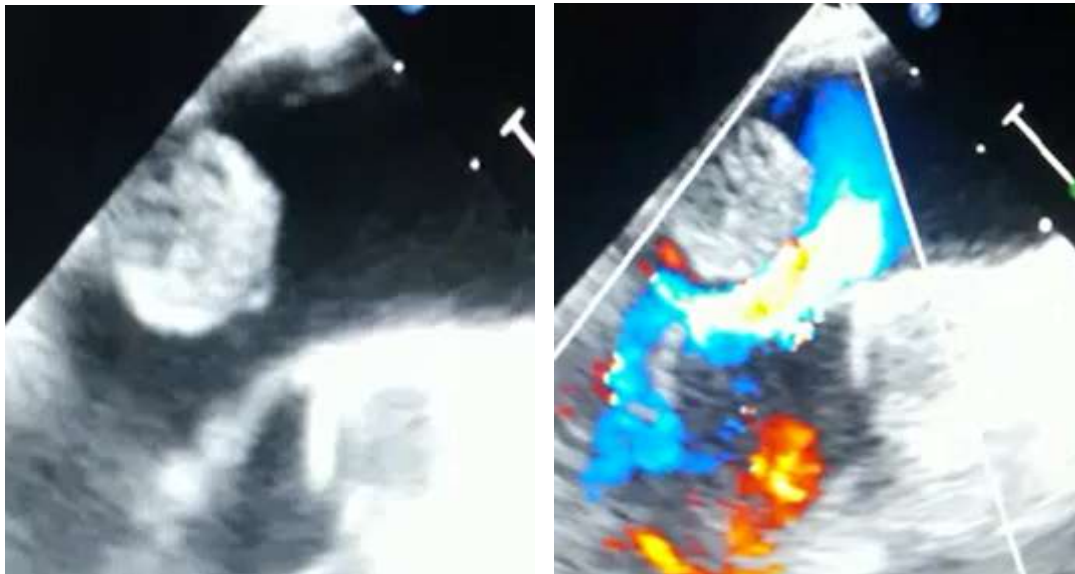
Histological examination of the various samples shows a benign mesenchymal tumor formation characterized by a proliferation of spindle-shaped cells, sometimes with a star-like appearance. The background is myxoid and congestive.

The post-operative period was marked by a nosocomial pulmonary infection with bilateral pulmonary embolism. Patient was symptom free 8-month post-operation, with no sign of tumor recurrence or mitral valve dysfunction in trans-thoracic echocardiography (**fig 4**).



**Figure 4:** Post-operative TEE free of residual mass.

In November 2020, the patient consults for exertional dyspnea with an image at the TTE and TOE evoking a recurrence of myxoma of the left atrium (**fig5**).



**Figure 5:** TTE revealing a probable recurrence of myxoma of the left atrium.

### DISCUSSION

Cardiac myxoma remains the most common intracardiac tumor.

The majority of myxomas occur in the left atrium (75%). In this location, the myxoma may have cardiac, general, neurological or arterial expression. Cardiac manifestations may include signs of paroxysmal mitral stenosis or regurgitation, positional syncope, palpitations, dyspnea, chest pain or heart failure.

The diagnostic method of choice is trans-thoracic echocardiography, which has a sensitivity of 95% (2,3,4).

Patients usually have a good prognosis after resection.

The recurrence rates are extremely low in the general population. The first case of myxoma recurrence, which occurred several years after surgical removal, was described by Gerbod et al in 1967 (5). It can emerge within a few months to several years after surgical excision with an average of 3 to 4 years.

Several mechanisms have been suggested for these recurrences (6,7). The first explanation is incomplete excision of the tumor. In our patient the original tumor was totally excised but microscopic sections demonstrated that the tumor is extend beyond the margin of excision. Hence, inadequate excision may be a cause of the recurrence. The second and third explanation are respectively the implantation of embolic fragments of the original tumor in the myocardium spontaneously or due to a previous surgery or recurrence occurring from a pretumor focus present in another part of the myocardium. It can also be explained by the malignant transformation of the tumor or by familial predisposition for recurrence. The last explanation is growth from "pre-tumor" cells in the atrial septum. Whether they arise from remnants of myxoid tissue or from endothelial elements, myxomas are generally attached to the region of the fossa ovalis. This hypothesis may also be valid for our patient whose recurrence was in the region of the fossa ovalis.

To avoid recurrence, open heart chambers are examined carefully and manipulations during surgery are minimized to prevent intraoperative embolization until aortic cross-clamping.

#### CONCLUSION

Despite the benign nature of cardiac myxoma, cardiac and extra-cardiac complications and the risk of recurrence make it a serious disease. To avoid the risk of recurrence an intraoperative examination of all the cardiac cavities for multifocal diseases, resection of the tumor at the same time as the the underlying tissue must be rigorous and regular clinical and echocardiographic monitoring of patients must be initiated for early detection of recurrences.

#### REFERENCES

1. Lone RA, Ahanger AG, Singh S, et al.: Atrial myxoma: trends in management. *Int J Health Sci.* 2008, 2:141-151.
2. Nomeir AM, Watts LE, Seagle R, Joyner CR, Corman C, Prichard RW. Intracardiac myxomas: twenty-year echocardiographic experience with review of the literature. *J AmSoc Echocardiogr* 1989;2(2):139–50.
3. Obeid AI, Marvasti M, Parker F, Rosenberg J. Comparison of transthoracic and transesophageal echocardiography in diagnosis of left atrial myxoma. *Am J Cardiol* 1989 Apr 15;63(13):1006–8.
4. Roeltgen D.P., Weimer G., Patterson L.F. Delayed neurologic complications of the left atrial myxoma. *Neurology*, 1981, 31, 8-13.
5. GERBODE, F., KEETTH, J. W., AND HILL, D. J.: Surgical management of tumors of the heart. *Surgery* 61: 94, 1967.
6. Kothari J, Lakhia K, Solanki P, Panchal J, Shah P: Recurrent left atrial myxoma in a young patient: a rare entity. *J Clin Diagn Res.* 2016, 10:05-07. [10.7860/JCDR/2016/20425.8321](https://doi.org/10.7860/JCDR/2016/20425.8321)
7. Jia X, Kohli A, Jarjour J, Chen CJ, Gilmore B, Tabbaa R, Poythress EL: Recurrent biatrial myxoma in a 41-year-old woman after left atrial myxoma resection. *Tex Heart Inst J.* 2017, 44:402-404. [10.14503/THIJ-16-6017](https://doi.org/10.14503/THIJ-16-6017)