

Takotsubo Syndrome

Lalla Fatima Ezzahra El Hassani¹, Salwa Cheraou², Nawal Doghmi³, Mohamed Cherti⁴

^{1,2}MD; Department of cardiology, Ibn Sina University Hospital Center, Rabat, Morocco

^{3,4}Phd. Department of cardiology, Ibn Sina University Hospital Center, Rabat, Morocco

ARTICLE INFO

Publication Online:
22 May 2019

ABSTRACT

Introduction: Acute cardiomyopathy or Tako-Tsubo syndrome (TTS) is a transient acute cardiac phenomenon characterized by apical, mid-ventricular or more rarely basal atresia of the left ventricle (LV) that mimics the symptoms of acute coronary syndrome (ACS).

Materials and methods: This work is a descriptive retrospective study over a 14-month period involving 5 cases of TTS.

The objective: is to focus on the main clinical, electrical, coronary and radiological features of the TTS.

Outcome: the prevalence of STT on all ACS during the study period; was 5.1%. The representation is exclusively female. The average age was 64 years old. Psychic stress was a common triggering factor for the entire study population. Chest pain was the main symptom. The electrical signs were dominated by signs of ischemic epicardial ischemia with only one case of endocardial ischemia. All patients had an initially elevated troponin. Acute echocardiography demonstrated segmental kinetic disorders with transient left ventricular dysfunction. The entire population did not have significant coronary angiography. MRI did not indicate late enhancement or lack of perfusion or edema.

Corresponding Author:
Salwa Cheraou

KEYWORDS: Tako-tsubo syndrome, electrocardiography, angiography, MRI.

INTRODUCTION

Acute stress cardiomyopathy or Tako-Tsubo syndrome (TTS) is a transient acute cardiac phenomenon characterized by apical, medio-ventricular or more rarely basal atresia of the left ventricle (LV) that mimics the symptoms of acute coronary syndrome (ACS). It is characterized by the absence of angiographically significant coronary stenosis and a characteristic apical ballooning aspect of LV at the systolic time of ventriculography [1]. Thus, if this nosological entity corresponds clinically to a normal coronary ACS, identifying it in emergencies in its particular context of stress allows most often to avoid unnecessary explorations and treatments. Our study will take stock of the clinical, coronary and radiological features of Tako-Tsubo.

METHOD

Our work is a descriptive retrospective study of 5 cases of Tako-Tsubo, treated and followed over a period of 14 months, in the cardiology department B of the IBN SINA hospital in Rabat. Included in the study population were patients admitted to the Cardiology B department, in whom the diagnosis of Tako-Tsubo's disease was retained on coronary and radiological evidence. Incomplete files were excluded.

RESULT

Patients were all hospitalized and recorded at least once by Cardiology B, which reported 97 cases of ACS over the same period: the prevalence in our TTS series for all ACS was 5.1% with an exclusive female presentation and an average age of 64 years.

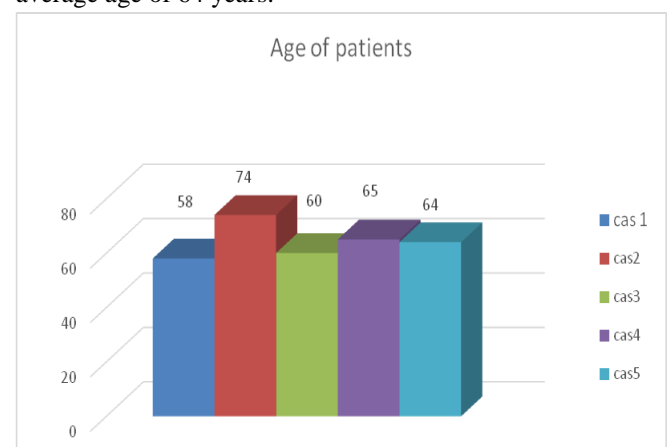


Figure 1: Graphical representation of the age of our patients

Only one case in our series had a history of replacement mitral valve by a mechanical prosthesis. Menopause was a

“Takotsubo Syndrome”

common cardiovascular risk factor among our 5 patients, the others are mainly high blood pressure (hypertension) and diabetes.

Our 5 patients had in common a psychic field of emotional or physical stress during the occurrence of chest pain.

The clinical signs that constituted the reason for consultation were mainly infarctoid chest pain isolated in 4 cases, associated with dyspnea in a single case.

No deaths have been reported in our series.

Only one ECG had an anterior-septo-apical shift.

Other abnormalities found were: negative T waves in different territories or electrical signs of endocardial ischemia.

The troponin assay was performed and positive in all of our patients. The positivity threshold $> 0.014\text{ng} / \text{l}$ was considered.

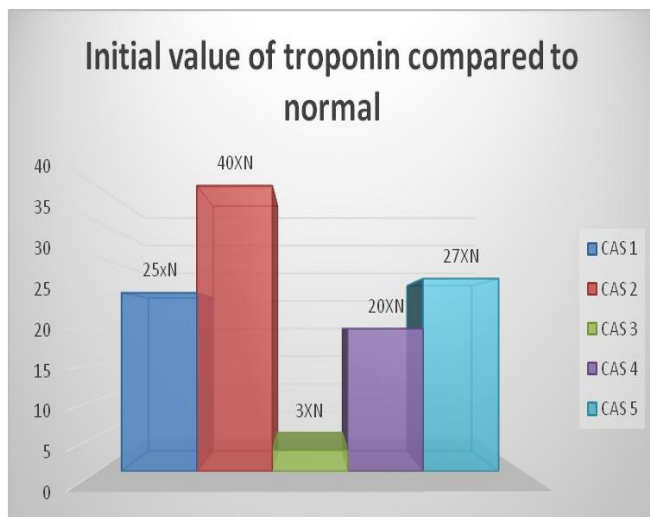


Figure 2 : Initial value of troponin compared to normal

Evolution of the kinetics of troponin; reassessed during the first week of patient hospitalization, within 24 hours to 72 hours; was marked by a decrease in control troponin levels compared to the initial value.

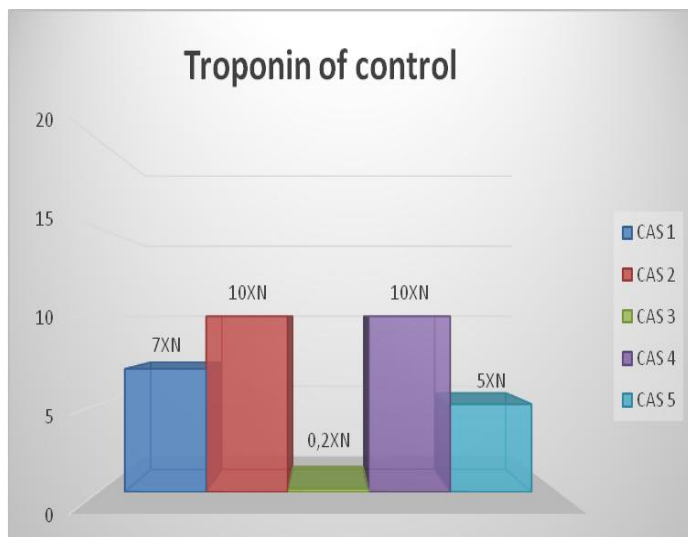


Figure 3 : Troponin of control

The entire study population had LV dysfunction during admission and segmental kinetic disorders dominated mainly by akinesia.

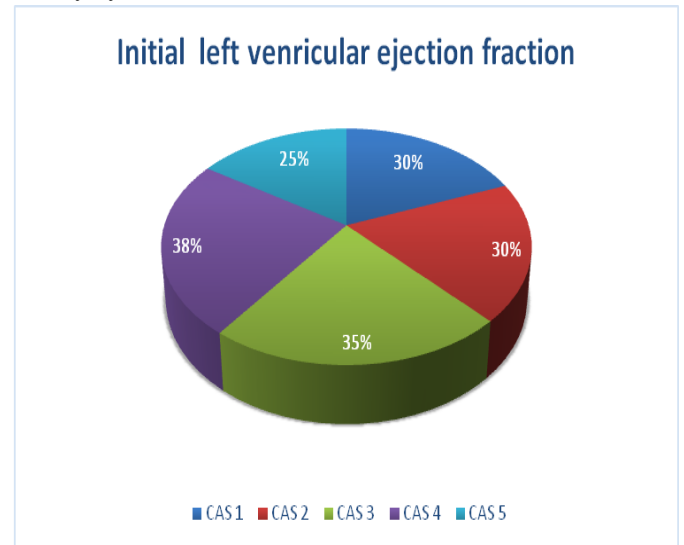


Figure 4 : Left ventricular ejection fraction at admission

Ultrasound control; variable duration of 2 days to one week of hospitalization had demonstrated an improvement in LV function in 3 patients, the 2 others had moderate ventricular dysfunction with an average LVEF of around 50% (47% as a minimum) found in the third case and 55%: maximum value in the first case of the series).

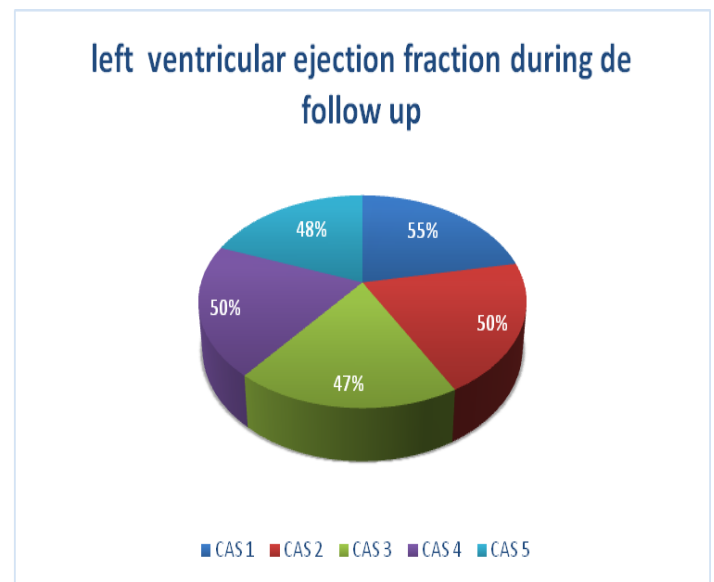


Figure 5 : Left ventricular ejection fraction during de follow up.

No coronary angiography in the series reported significant coronary lesions.

MRI performed at a distance from the acute phase made it possible to look for the presence of a late enhancement or edema, to assess the quality of the perfusion, to evaluate the kinetics, to measure the diameters, the ventricular volumes and the LVEF.

The MRI of patients in our series did not show late enhancement or perfusion defect or edema.

DISCUSSION

In 1990, Satoh et al. [1] described for the first time the entity named tako tsubo by analogy between the observed strain of LV and the shape of a fishing vessel used in Japan, with a bulging bottom and a narrow neck. While the syndrome has more than 75 names [2] the name Tako Tsubo has been validated by the European Society of Cardiology (ESC) and remains the most widely used in the literature [3].

This stress cardiomyopathy is much more common in women than in men (80 to 100%).

The average age of onset of this syndrome is 61 to 76 years. The same epidemiological finding was reported in our study. The mechanism of taku-tsubo syndrome remains hypothetical until now. Previous studies and observations have established that akinetic territory does not correspond to coronary arterial territory. The syndrome is therefore not explained by the obstruction of the supracardiac coronary arteries nor by a coronary spasm. [4,5]

The current hypothesis is that of excessive catecholaminergic stimulation which alters cardiomyocytes, their metabolism and microcirculation. The occurrence of TTS in a context of emotional stress supports this hypothesis. Plasma levels of noradrenaline and adrenaline were 2 to 3 times higher [6].

In our series, all patients experienced physical or mental stress, which reinforces the catecholaminergic theory.

The TTS corresponds to a pathology whose definition was specified by the 2004 Mayo Clinic criteria, modified in 2008 [7] [8]

Table 1: Mayo clinic criteria

A	Transient dyskinesia of left mid-ventricular segment with or without apical involvement
B	Absence of obstructive coronary artery disease
C	New EKG abnormalities (ST segment elevation or T wave inversion) or mild troponin elevation
D	Absence of pheochromocytoma and myocarditis

Table1 : Mofified Mayo Clinic criteria – 2007 (4 criteria must be present)

The ESC proposes in its consensus an update with introduction of interTAK criteria. The main changes from the previous criteria are as follows:

- ♣ Pheochromocytoma is no longer excluded from the diagnosis of STT.
- ♣ The presence of coronary disease objectified to coronary angiography is no longer in contradiction with the diagnosis of STT.

The possibility of rare cases of kinetic disorder in an arterial territory (focal TTS).

International diagnostic criteria for TTS (interTAK criteria): [9]

1. Transient left ventricular dysfunction (hypokinesia, akinesia or dyskinesia) with apical ballooning or medial, basal or focal kinetic disturbances. Right ventricular involvement may be associated. These transitory parietal kinetic disorders generally exceed a territory of vascular systematization; however, rare cases may exist with involvement of an arterial territory (focal TTS).
2. An emotional, physical or combined trigger may precede the occurrence of the TTS.
Neurological disorders (subarachnoid haemorrhage, stroke, TIA, etc.) or pheochromocytoma may be triggers for TTS.
3. Modifications of the ECG are present (ST segment superset or downsampling, T wave inversion, QTc interval prolongation). However, there are cases without ECG modification.
4. Cardiac biomarkers (troponin and CPK) are moderately increased.
A significant rise in the BNP is frequent.
5. Significant coronary involvement is not inconsistent with an TTS.
6. There is no argument for myocarditis.
7. Women after menopause are mainly affected.

The incidence of classical cardiovascular risk factors is lower than for ACS [10]. Our study also did not correlate the presence of cardiovascular risk factors with the occurrence of TTS.

The usual tell-tale symptom is chest pain, sometimes associated with digestive nausea and vomiting. This chest pain was the reason why the majority of our patients had consulted. It can also be a dyspnea, more rarely lipothymia, or even syncope or palpitations.

The initial clinical presentation may reflect serious complications: heart failure, acute pulmonary edema or cardiogenic shock [7].

The physical examination is nonspecific and often normal except for regular irregular tachycardia related to fast atrial fibrillation (case # 3 of the series). However, in case of associated dyspnea, the patient frequently has pulmonary auscultation suggestive of congestive heart failure (case # 3 of the series).

ECG abnormalities are almost always present in the acute phase [11,12]. Repolarization disorders are observed, of which ST segment elevation in precordial shunts is the most frequent initial representation (67-75%), followed by T-wave inversion (61%) [12]. However, this elevation was found in a single patient of the series (case # 5, Figure 3). Sometimes only the diffuse and ample inversion of the T waves is noted. 4 out of 5 patients in our study had negative T waves. This inversion appears in particular during the first few hours, in the days and weeks following the onset of

“Takotsubo Syndrome”

symptoms, It may persist longer than left ventricular kinetic disorders.

However, an ECG initially normal or with nonspecific abnormalities of repolarization is observed in 7 to 15% of patients with this acute cardiomyopathy [13, 14].

ECG elements suggestive of diagnosis:

- There is no over-sloping of the ST segment in V1, discordant with the ST superstructure in V2 V3, whereas the ECG involvement seems circumferential.

- Sub-deceleration of ST segment with negative T wave at aVR.
- ECG appearance of SCA in the anterior territory associated with an extended QT interval.
- ECG appearance of SCA associated with episodes of torsades de pointes.

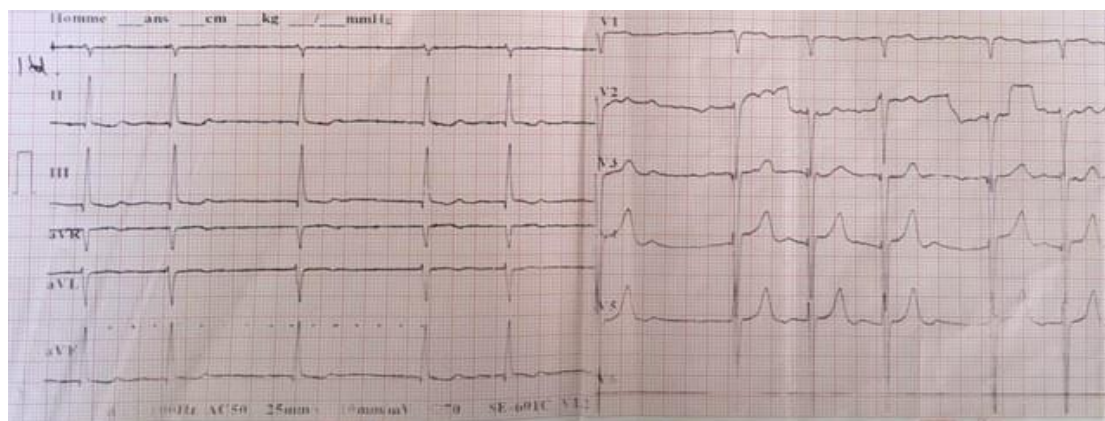


Figure 6 : ECG of a patient with acute Tako-Tsubo syndrome (Case 5)

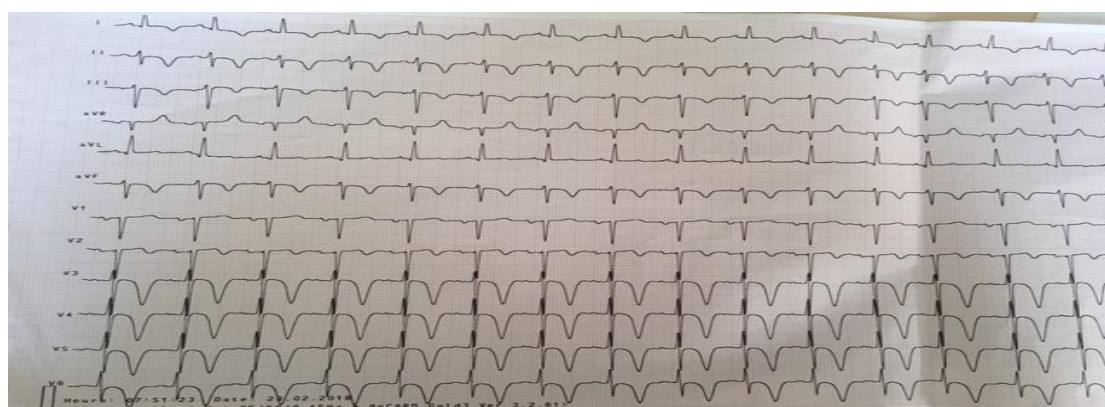


Figure 7 : 48-hr ECG of a patient with Tako-Tsubo syndrome showing diffuse, negative T waves (Case 2)

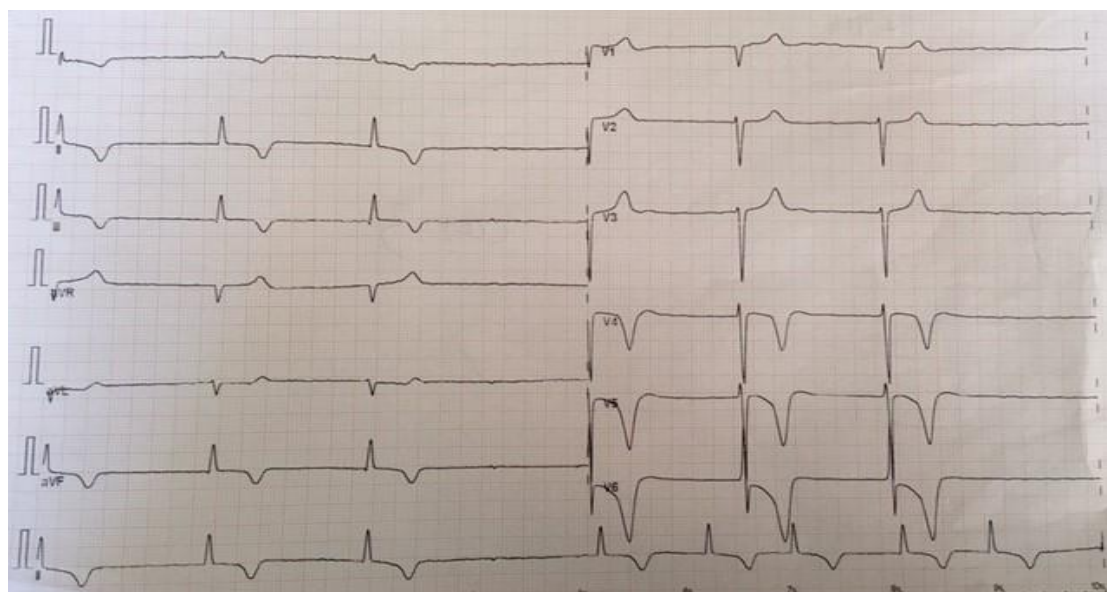


Figure 8. Electrocardiogram of TTS showing a negativation of apico-lateral and inferior T-waves with prolonged QT (Case 3)

“Takotsubo Syndrome”

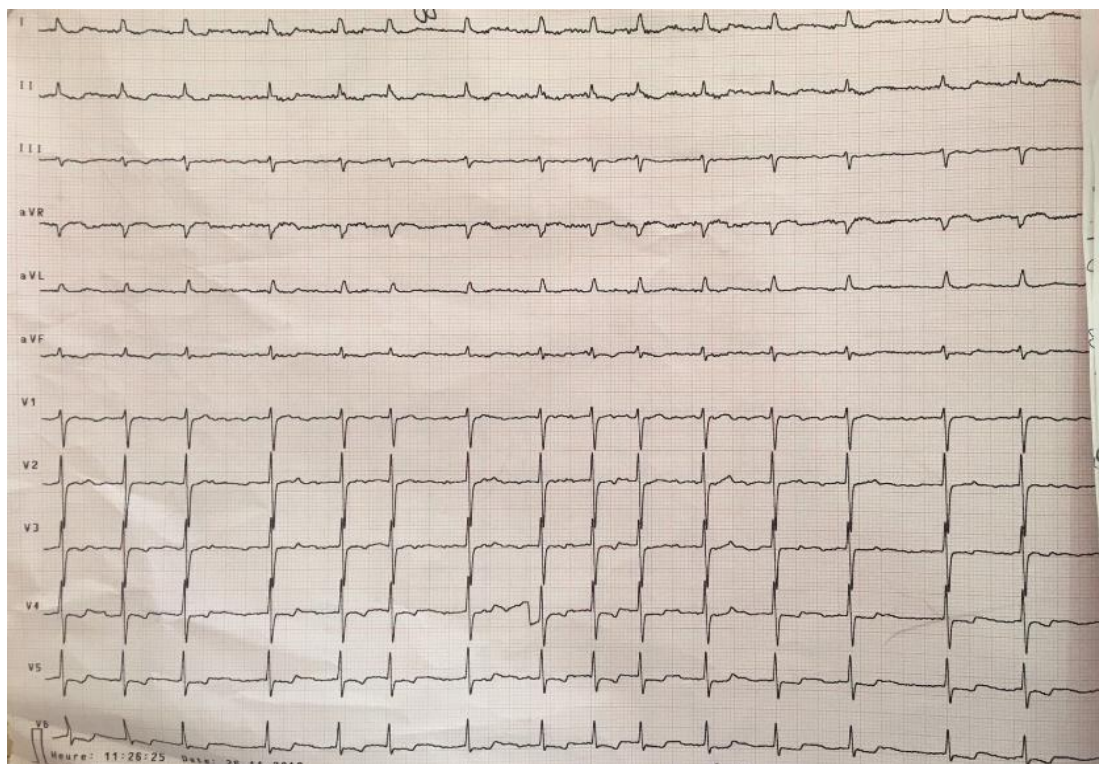


Figure 9 : FA with ST segment offset in apico-lateral low with negative T waves in inferior (Case 4)

Cardiac markers, particularly troponin, are elevated in 90-93% of cases but in lower proportions than those seen in ST segment elevation SCA and decreased during hospitalization [15, 16]. The same observation was described in our study.

The echocardiography trans thoracic can help the diagnosis by objectifying the characteristic deformation of the VG: important disorders of the kinetics (hypokinesia and / or akinesia of the apical segments +/- median of the VG (or more rarely basal) with ballooning of the two-thirds apicals respecting its portion Hyperkinetic Basal In our study, the average LVEF measured at the echocardiography trans thoracic of admission was very close to the value of 31.6%, and the kinetic disorders described in the literature are about the same. same found in our patients.

The control echocardiography trans thoracic also makes it possible to follow the course of the disease with a marked improvement of the kinetic and LVEF disorders in an average of 3 weeks in more than 90% of cases [7, 17].

In our study the evolution was marked by an improvement of the LVEF compared with that of the acute phase and a restoration of a satisfactory kinetics in the majority of the study population. This fits perfectly with the data of literature. The average LVEF control was 50%. These results support the hypothesis of reversible ventricular dysfunction secondary to myocardial involvement underlying the pathogenesis of TTS [18, 19].

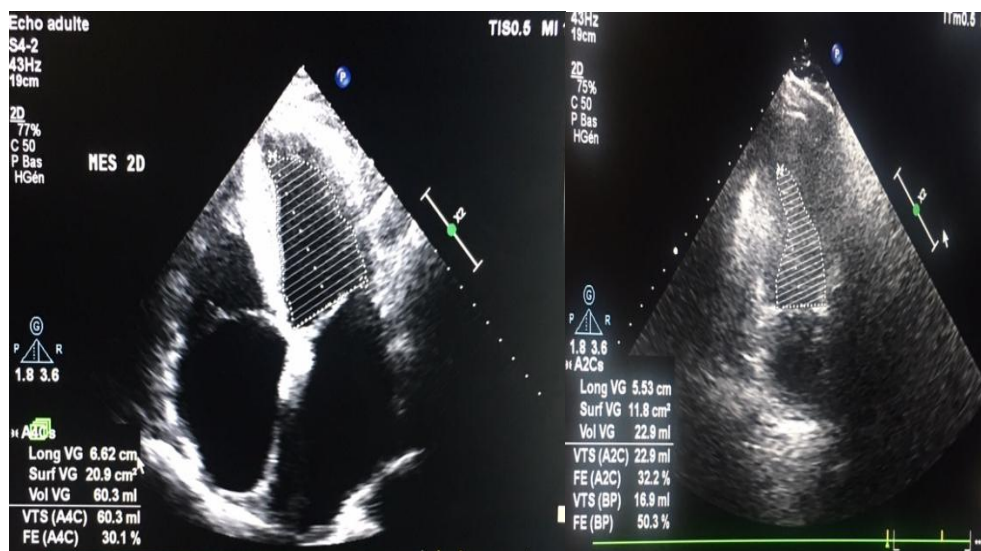


Figure 10a: Ultrasound images of the initial left ventricular ejection fraction and its evolution of Case 1

“Takotsubo Syndrome”

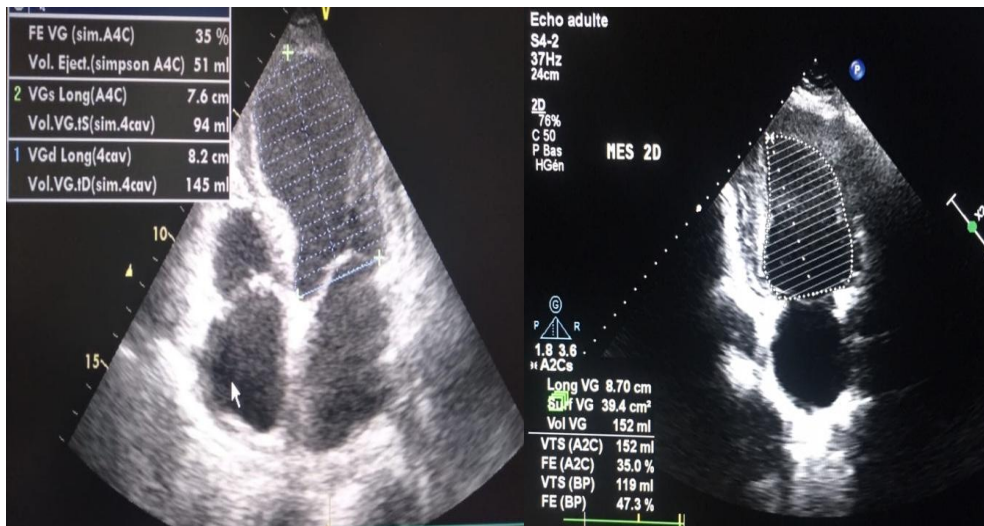


Figure 10b : Ultrasound images of the initial left ventricular ejection fraction and its evolution of Case 3 balloon appearance

The anomalies of segmental kinetics do not correspond to coronary vascular territories and their extent is disproportionate compared to the low enzymatic rise [20]. Depending on its availability, MRI that confirms a viable myocardium can participate in the diagnosis and follow-up of the STT [21]. It distinguishes myocarditis and ACS and evaluates abnormalities in VG kinetics and LVEF.

The MRI was performed on all our patients in a variable time frame on average 3 weeks compared to the date of admission within our department.

The classical and typical MRI appearance of Tako -Tsubo cardiomyopathy associates disorders of apical LV

contraction with the absence of gadolinium-mediated myocardial enhancement. The contractile abnormality is in the form of a ballooning of the LV whose apical region does not contract (or very little) in systole. This aspect was found in all patients in the study. The T2 sequences show a hyperintensity in the dysfunctional zone corresponding to an edema secondary to myocardial inflammation. Hypersignal T2 was found in two patients of our series (4th and 5th case).

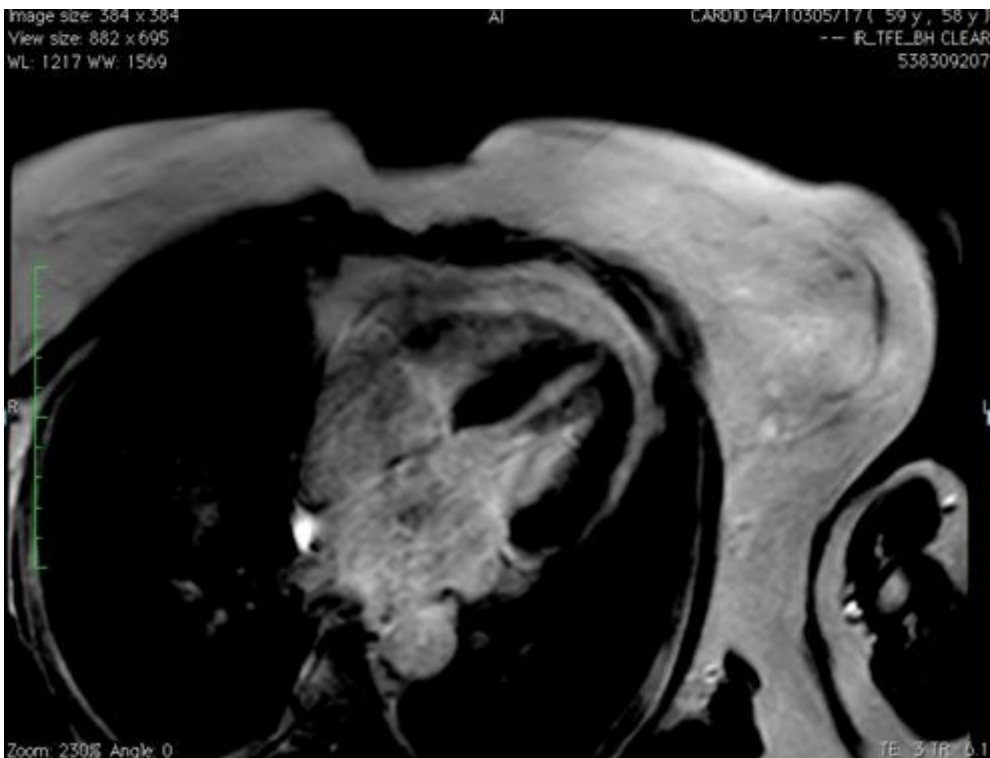


Figure 11 : MRI section 4 cavities in late enhancement sequence 10 minutes after gadolinium injection showing no contrast enhancement

“Takotsubo Syndrome”

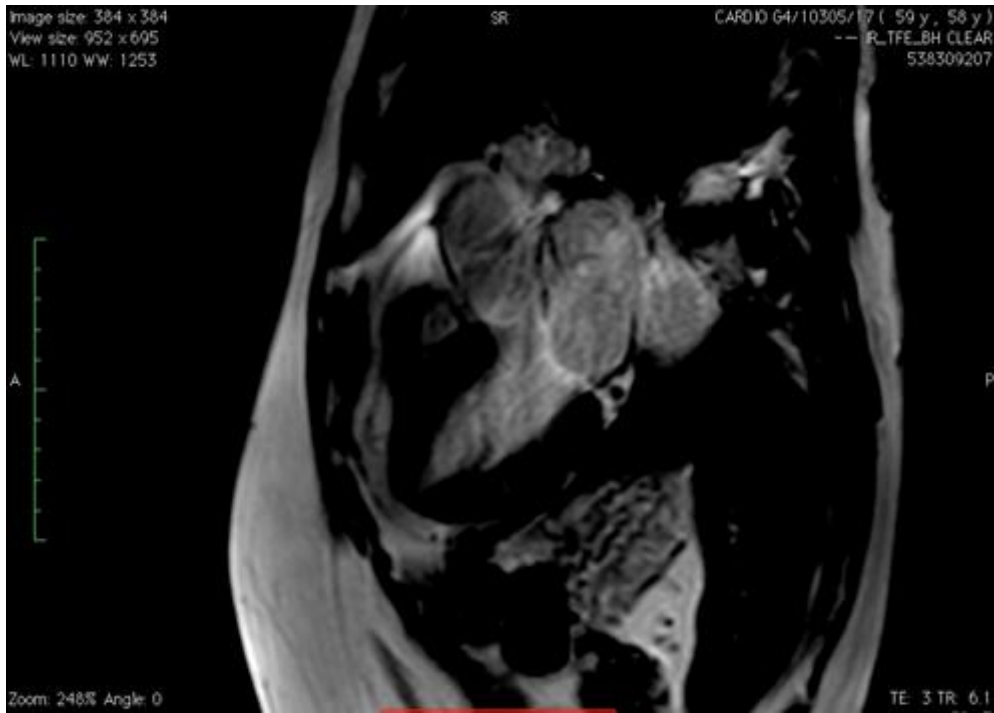


Figure12 : MRI section 2 cavities in late enhancement sequence 10 minutes after Gadolinium injection showing no contrast enhancement

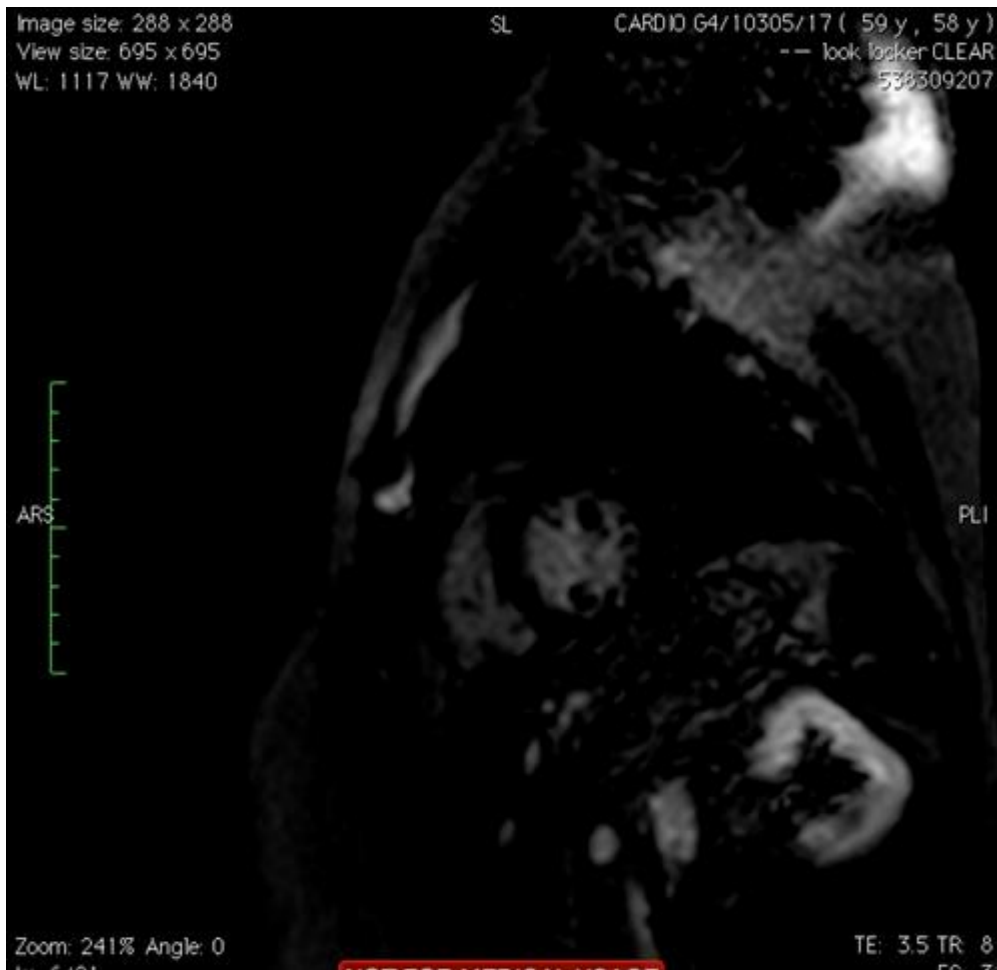

Figure 13 : Small axis MRI cut in late enhancement sequence 10 minutes after Gadolinium injection showing no contrast enhancement

“Takotsubo Syndrome”

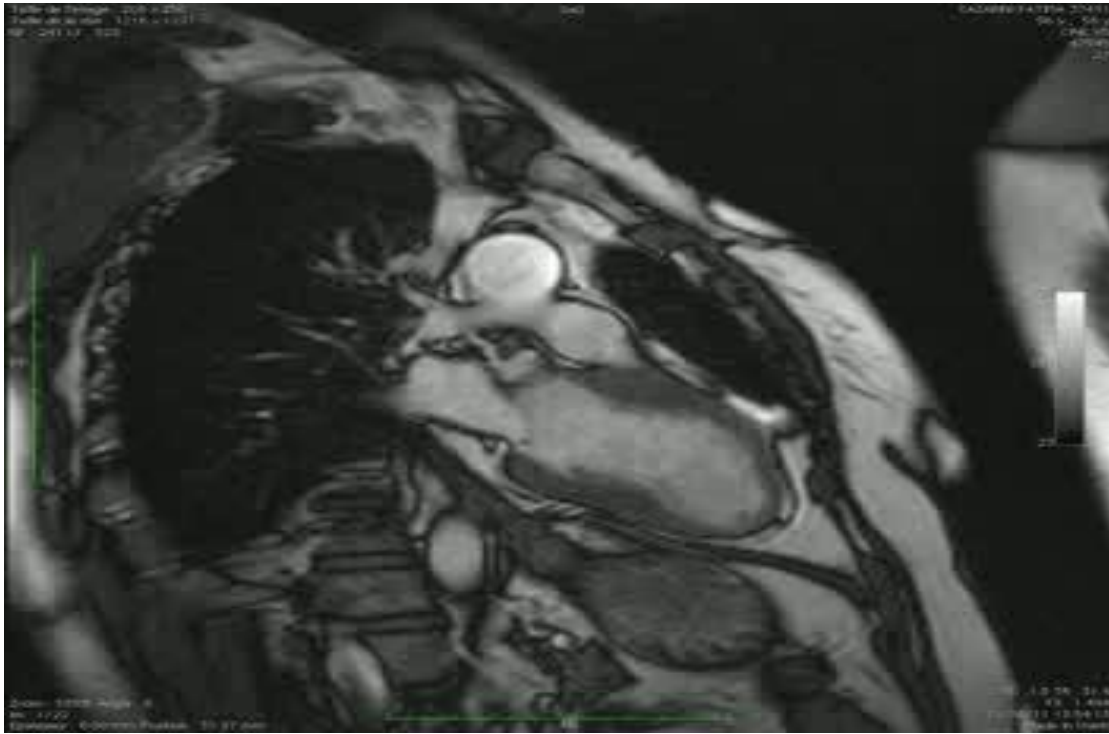
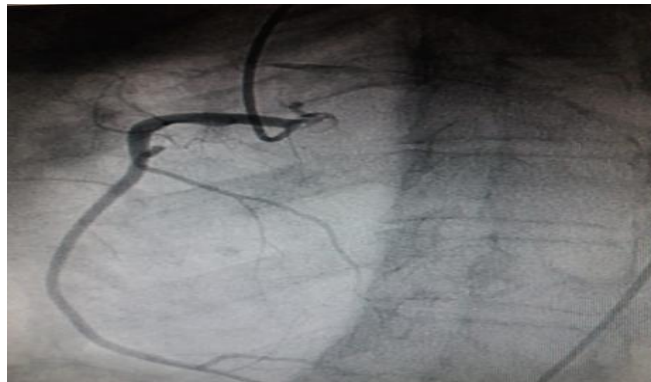


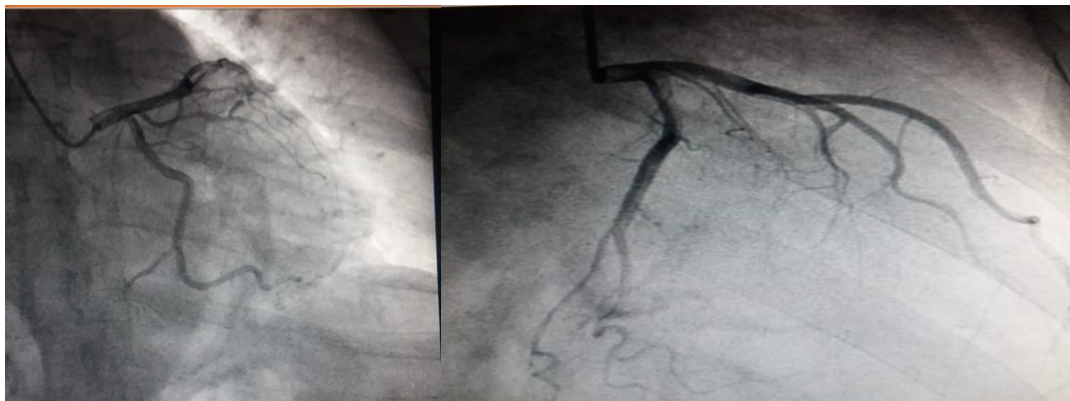
Figure 14 : Section 2 Cavities showing localized akinesia at the tip of the left ventricle (Case 5)

However, most often, the initial presentation explains the use of a coronarography from the outset upon admission to the suspicion of an ACS. This examination found no significant coronary lesion [11]; rare cases of multifocal spasm (IVA and circumflex) have been described [12].

In our series, the 5 patients had coronary angiography that had not revealed significant coronary lesions or spasm of the coronary arteries. The time of realization ranged from 5 days to a week on average compared to the day of admission.



a: Coronary images showing a right coronary artery uninjured



b: Coronary images showing a lesion-free left coronary network

Figure 15(a+B) : Coronarographic images of the patients of the series objectifying a healthy coronary network

Because the TTS imitates the ACS in its clinical presentation the emergency physician is most often brought to initiate the treatment of an ACS according to the current recommendations [11,22,23]. There is no contraindication to the use of standard treatments such as platelet antiaggregants and aspirin, the interest of this anti-aggregation to MRI even if smooth coronary so as not to ignore a Embolic mechanism or plate breakage went unnoticed. It may or may not be associated with antiGP IIB / IIIa and anti-coagulants [11,22,23]. Although thrombolytics are not beneficial to patients with TTS, they have often been used when coronary angiography was not available within the recommended time frame. In these cases, there was no secondary excess mortality related to TTS [24,25,25]. The patient who presented for a shift in our series had not benefited from thrombolysis in front of the atypical aspect of the offset. In contrast, all patients received antiplatelet and anticoagulation therapy in the presence of suspected ACS.

Beta-blockers (BB) improve the LVEF and decrease the repolarization disorders [25,27]. Converting enzyme inhibitors (ACE inhibitors) and calcium channel blockers improve coronary blood flow and LV remodeling [24, 25,26] For this, a basic treatment of ischemic heart disease mainly based on BB and inhibitor of conversion enzyme was prescribed in all patients in the study. Congestive heart failure of TTS has no specificity of management. Case # 3 in our series was treated with diuretics with a very good clinical course during hospitalization.

Secondary management is that of LV dysfunction; it is based on the prescription of inhibitor of conversion enzyme and BB more or less associated with diuretics for a typical duration of approximately 3 months; until the normalization of the LV function. The inhibitor of conversion enzyme and BB could potentially reduce the recurrence rate of TTS [28]. The patient discharge order included a BB associated with ACE inhibitor with and, depending on the case, a diuretic, an anticoagulant and a lipid-lowering agent.

The decision to stop treatment by inhibitor of conversion enzyme and BB is dictated by the standardization of the LVEF. However, it is traditional to see the patients at one year to ensure the proper evolution.

Recurrences are reported in 0% to 8% of cases [7]. In our series, only one case of recurrence was noted in a period of around 11 months due to emotional stress.

CONCLUSION

The prevalence of TTS remains rare but its incidence in clinical practice is increasing in the ACS. Given the best knowledge of its anamnestic, clinical, ECG and coronarographic characteristics, the main challenge for the emergency physician is to be able to evoke the diagnosis during the initial presentation, in order to avoid the use of cardiac therapies not devoid of side effects and limit

unnecessary investigations. The pathophysiology of this syndrome remains to be defined but several studies are in favor of an exaggerated reaction of beta-adrenergic receptors to a catecholamine discharge. The prognosis is indeed favorable but must take into account potentially severe complications that may occur during the acute phase of the pathology. The establishment of national registers and referral centers for this pathology should allow for the establishment of more detailed prospective studies. Indeed, lines of research are still to be developed in order to determine the pathogenesis and the optimal therapeutic management of this syndrome, which must now provoke a reflection allowing a better understanding of its mechanisms and a better adapted approach to its therapeutic management. in the years to come.

REFERENCES

1. Sato H., Tateishi H, Uchida T, et al. Kodama K, Haze K, Hon M, eds. Clinical Aspect of Myocardial Injury: From Ischaemia to Heart Failure. Tokyo: Kagakuhyouronsya; 1990 : 56-64
2. Sharkey SW, Lesser JR, Maron MS, Maron BJ. Why not just call it tako-tsubo cardiomyopathy: a discussion of nomenclature. *J Am Coll Cardiol* 2011; 57: 1496-7.
3. Lyon AR, Bossone E, Schneider B, et al. Current state of knowledge on Takotsubo syndrome: a position statement from the Taskforce on Takotsubo Syndrome of the Heart Failure Association of the European Society of Cardiology. *Eur J Heart Fail* 2016; 18: 8-27
4. Finsterer J, Stollberger C. Neurological and non-neurological triggers of Takotsubo syndrome in the pediatric population. *Int J Cardiol* 2015; 179: 345-7.
5. Bossone E, Savarese G, Ferrara F, et al. Takotsubo cardiomyopathy: overview. *Heart Fail Clin* 2013; 9: 249-66.
6. Kurowski V, Kaiser A, Von Hof K, Killermann DP, Mayer B, Hartmann F, et al. Apical and midventricular transient left ventricular dysfunction syndrome (takotsubo cardiomyopathy). Frequency, mechanisms, and prognosis. *Chest* 2007;132:809–16.
7. Bybee K.A., Kara T., Prasad A. et al. Systematic review: transient left ventricular apical ballooning: a syndrome that mimics ST-segment elevation myocardial infarction. *Ann Intern Med.* 2004 ; 141 (11) : 858-65
8. Kawai S., Kitabatake A., Tomoike H. Guidelines for diagnosis of takotsubo (ampulla) cardiomyopathy. *Circ J.* 2007 ; 71 (6) : 990-2
9. Jelena-Rima Ghadri and al. International Expert Consensus Document on Takotsubo Syndrome (Part II): Diagnostic Workup, Outcome, and

- Management, *European Heart Journal*, Volume 39, Issue 22, 7 June 2018, Pages 2047–2062
10. Donohue D., Movahed M.R. Clinical characteristics, demographics and prognosis of transient left ventricular apical ballooning syndrome. *Heart Fail Rev.* 2005 ; 10 (4) : 311-6
 11. Gianni M., Dentali F., Grandi A.M., Sumner G., Hiralal R., Lonn E. Apical ballooning syndrome or takotsubo cardiomyopathy: a systematic review. *Eur Heart J.* 2006 ; 27 (13) : 1523-9
 12. Sharkey SW, Lesser JR, Zenovich AG, et al. Acute and reversible cardiomyopathy provoked by stress in women from the United States. *Circulation* 2005 ; 111 : 472-
 13. Pavin D, Le Breton H, Daubert C . Human stress cardiomyopathy mimicking acute myocardial syndrome. *Heart* 1997 ; 78 : 509-11
 14. Finsterer J, Stollberger C. Neurological and non-neurological triggers of Takotsubo syndrome in the pediatric population. *Int J Cardiol* 2015; 179: 345-7
 15. Lyon AR, Bossone E, Schneider B, et al. Current state of knowledge on Takotsubo syndrome: a Position Statement from the Taskforce on Takotsubo Syndrome of the Heart Failure Association of the European Society of Cardiology. *Eur J Heart Fail* 2016; 18: 8-27. (Review)
 16. Templin C, Ghadri JR, Diekmann J, et al. Clinical Features and Outcomes of Takotsubo (Stress) Cardiomyopathy. *N Engl J Med* 2015; 373: 929-38
 17. Afonso L., Bachour K., Awad K., Sandidge G. Takotsubo cardiomyopathy: pathogenetic insights and myocardial perfusion kinetics using myocardial contrast echocardiography. *Eur J Echocardiogr.* 2008 ; 9 (6) : 849-54
 18. Lang RM, Badano LP, Mor-Avi V, et al. Recommendations for cardiac chamber quantification by echocardiography in adults: an update from the American Society of Echocardiography and the European Association of Cardiovascular Imaging. *Eur Heart J Cardiovasc Imaging* 2015; 16: 233-70. (Review)
 19. Wittstein IS. Stress cardiomyopathy: a syndrome of catecholamine-mediated myocardial stunning? *Cell Mol Neurobiol* 2012; 32: 847-57. (Review)
 20. Tsuchihashi K, Ueshima K, Uchida T, et al. for the Angina Pectoris-Myocardial Infarction Investigations in Japan. Transient left ventricular apical ballooning without coronary artery stenosis : a novel heart syndrome mimicking acute myocardial infarction. *J Am Coll Cardiol* 2001 ; 38 : 11-8
 21. Lipiecki J, Durel N , Decalf V, et al. Ballonisation apicale transitoire du ventricule gauche ou syndrome du tako-tsubo. *Arch Mal Cœur* 2005 ; 98 : 275-80
 22. Pilgrim T. M., Wyss T. R. Takotsubo cardiomyopathy or transient left ventricular apical ballooning syndrome: A systematic review. *Int J Cardiol.* 2008 ; 124 (3) : 283-92
 23. Prasad A., Lerman A., Rihal C.S. Apical ballooning syndrome (Tako-Tsubo or stress cardiomyopathy): a mimic of acute myocardial infarction. *Am Heart J.* 2008 ; 155 (3) : 408-17
 24. Sharkey S.W., Windenburg D.C., Lesser J.R. et al. Natural History and Expansive Clinical Profile of Stress (Tako-Tsubo) Cardiomyopathy. *J Am Coll Cardiol.* 2010 ; 55 (4) : 333-41
 25. Merchant E.E., Johnson S.W., Nguyen P., Kang C., Mallon W.K. Takotsubo cardiomyopathy: a case series and review of the literature. *West J Emerg Med.* 2008 ; 9 : 104-11
 26. Sealove B.A., Tiyyagura S., Fuster V. Takotsubo cardiomyopathy. *J Gen Intern Med.* Nov 2008 ; 23 (11) : 1904-8
 27. Bonacchi M., Valente S., Harmelin G. et al. Extracorporeal Life Support as Ultimate Strategy for Refractory Severe Cardiogenic Shock Induced by Tako-tsubo Cardiomyopathy: A New Effective Therapeutic Option. *Artif Organs.* 2009 ; 33 (10) : 86670
 28. Singh K, Carson K, Usmani Z, Sawhney G, Shah R, Horowitz J. Systematic review and meta-analysis of incidence and correlates of recurrence of takotsubo cardiomyopathy. *Int J Cardiol* 2014; 174: 696-701. (Review).