



Case Report of an Ischemic Stroke after Electrical Shock of Atrial Fibrillation Under Apixaban

Maryam NADIF¹, Meryem BENNANI², Soumia FAID³, Dania SRIFT⁴, Kawtar Manouri⁵, Sara Ahchouch⁶, Jamal Kheyi⁷, Hicham Bouzelmat⁸, Zouhair Lakhel⁹, Ali Chaib¹⁰

^{1,3,4,5,6,9} Intensive Care Unit of the Cardiology Center, Military Training Hospital Mohamed V, Rabat, Morocco

^{2,7,8,10} Rhythmology Service, Cardiology center, Military Teaching Hospital Mohamed V, Rabat, Morocco

ARTICLE INFO

ABSTRACT

Published Online:
22 November 2018

This article discusses the case of a patient with ischemic stroke following a cardioversion of Atrial Fibrillation under treatment with Apixaban 5 mg twice daily. Adherence to anticoagulant therapy and normal trans-thoracic ultrasound do not eliminate the possibility of an atrial thrombus, which may contraindicate or delay the cardioversion procedure. The use of transesophageal echocardiography in this case is discussed, to avoid the occurrence of thromboembolic events.

Corresponding Author:
Meryem BENNANI

This study indicates the need for further studies whether for flutter ablations or cardioversions under oral anticoagulants.

KEYWORDS: ischemic stroke ; electrical shock ; atrial fibrillation ; apixaban.

INTRODUCTION

Atrial fibrillation (AF) is the most common chronic cardiac rhythm disorder and is said to be non-valvular when not associated with underlying heart valve disease.

New molecules have been developed in non-valvular atrial fibrillation for the prevention of arterial thromboembolic events in subjects at risk: Direct oral anticoagulants, also known as direct anti-thrombotic drugs (dabigatran, rivaroxaban, apixaban, edoxaban).

They compete with Vitamin K antagonists, used for more than fifty years, showing a favorable risk-benefit profile, with a reduction in stroke, intracranial hemorrhage, mortality and a similar major bleeding rate, apart from more frequent gastrointestinal bleeding [1].

This article is about the case of a patient who presented an ischemic stroke as a result of electrical cardioversion of atrial fibrillation under apixaban treatment.

CLINICAL CASE

We report the case of a 72-year-old hypertensive patient with a history of flutter ablation. She was on Vitamin K antagonists, and then on apixaban 5 mg twice a day for one year and a half. The patient was admitted for electrical cardioversion of atrial fibrillation.

Transthoracic Echocardiography performed on admission found no abnormalities outside a dilated left atrium free echoes. Moreover, the patient reported good compliance. Apixaban treatment was continued after cardioversion.

Seventy-two hours after the procedure, the patient presented massive left hemiplegia, with facial involvement. The rhythm was still sinus with a lot of supraventricular extrasystole.

An urgent computed tomography (CT) scan of the brain was performed, showing early signs of right Sylvian stroke (Figure 1-2).

Thrombolysis is against-indicated in it, given the current anticoagulant therapy, hence the decision to stop antiagregant platelet and anticoagulant therapy because of the high risk of bleeding.

Magnetic resonance imaging (MRI) control twenty-four hours later, showed acute extended right Sylvian stroke, and electrocardiogram objectified atrial fibrillation.

A reassessment of the risk of haemorrhagic transformation is planned 12 days later, for the reintroduction of oral anticoagulants.

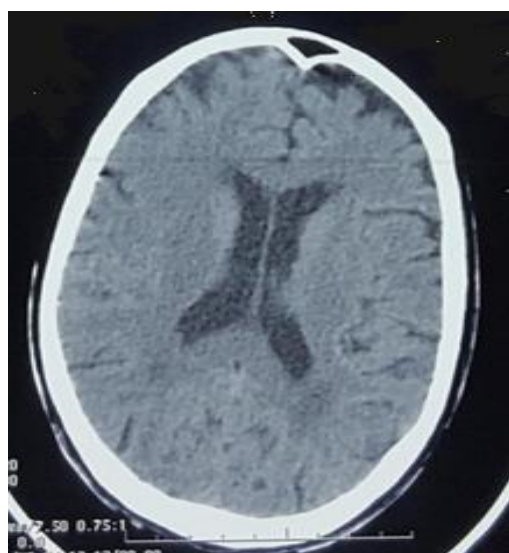


Figure 1: CT scan performed one hour after showing early signs of a right Sylvian stroke

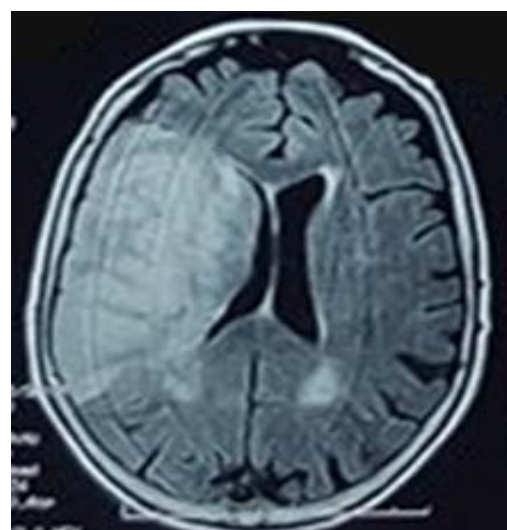


Figure 2: Cerebral MRI performed 24 Hours later showing extended right sylvian AVCI

2.1. Direct oral anticoagulants and atrial fibrillation

Direct oral anticoagulants, namely direct antithrombin (dabigatran) and factor Xainhibitors (rivaroxaban, apixaban, edoxaban) share several common features: they have a short half-life (compared with Vitamin K antagonists), their effectis not subject to large interindividual variations (unlike

Vitamin K antagonists), and therefore does not require monitoring of their anticoagulant activity (Table 1).

In addition, a significant part of their eliminationis renal and only Dabigatran has an antidote: Idarucizumab (PRAXBIND * for PRADAXA *).

Tableau 1 : Main pharmacological characteristics of direct oral anticoagulants.

| | Rivaroxaban [2] | Apixaban [3] | Edoxaban [4] | Dabigatran [5] | Vitamin K antagonists |
|----------------------------|--|---|---|--|---|
| Cible | Anti-Xa reversible | Anti-Xa reversible | Anti-Xa reversible | Anti-IIa direct reversible | Indirect : inhibition of synthesis of Vitamin K dependent factors (II, VII, IX, X) |
| Prodrog | No | No | No | Yes(étexilate) | No |
| Administrative | 1-2 /day | 2 /day | 1 /day | 1-2 /day | 1 /day |
| Bioavailability | 80% | 50% | >50% | 6-7% | 100% |
| Plasma Peaklevel | 2-4hours | 1-3hours | 1-2hours | 0,5-2hours | 4-5 days |
| Half-life | 5-11hours Increases with age (11-13hours) and kidney failure | 8-15hours Increases with age | 5-11 hours | 12-17 hours Increases with kidney failure (23-35 hours) | Acénocoumarol (9 hours) Fluindione (31 hours) Warfarine (36-42 hours) Phenprocoumon (5,5 days) |
| Kidney elimination pathway | 33 % in unchanged form and 33% in the form of inactive metabolites | 25 % (in unchanged form) | 35 % | > 85 % (in unchanged form) | No metabolism and liver elimination (CYP 1A2, 2C9, 2C19,3A4) |
| P-glycoprotein interaction | Yes | Yes | Yes | Yes | No |
| Cytochrome Interaction | Yes (3A4, 2J2) | Yes (3A4-5) | Yes (3A4-5) | À préciser | Yes |
| Surveillance | not systematic anti- Xa Activity if necessary | not systematic anti- Xa Activity if necessary | not systematic anti- Xa Activity if necessary | not systematic Thrombin time if necessary | INR |

| | | | | | |
|-----------------|------------------------------|------------------------------|------------------------------|------------------------------|-------------------------|
| Antidote | Not specific CPC possible | Not specific CPC possible | Not specific CPC possible | L'idarucizumab [6] | K Vitamin FFP or CPC |
|-----------------|------------------------------|------------------------------|------------------------------|------------------------------|-------------------------|

CPC : Concentrate Prothrombin complex, INR : *International normalized ratio*, FFP : Frozenfresh plasma.

They are indicated in the European Society of Cardiology's recommendations for the management of atrial fibrillation by 2010, with a clearer place in the update of these recommendations in 2016 [7].

These are anticoagulants, either direct oral anticoagulants, or Vitamin K antagonists, recommended treatments in class I (level of evidence A) in patients with CHA₂DS₂-VASc \geq 2 and indicated in recommendation class. IIa (level of evidence A) in patients with CHA₂DS₂-VASc score = 1.

The ARISTOTLE study of non-inferiority of apixaban vs warfarin [8] was performed in 18,201 patients with AF or atrial flutter, or with at least two episodes of electrocardiogram-documented AF or flutter more than two weeks and less than one year before inclusion. Patients received either 5 mg twicedaily apixaban or warfarin (INR between 2 and 3).

Strokes or systemic emboli were significantly reduced with apixaban 21% versus warfarin (HR 0.79, 95% CI 0.66-0.95) (p <0.01).

2.2. Oral Anticoagulants and Cardio version

Electrical cardioversion is associated with an increase in thromboembolic events in patients with atrial fibrillation. This risk is reduced by anticoagulation. The indication for anticoagulation in the period surrounding cardio version (3 weeks before and 4 weeks after) is based on observational studies of low enrollment and retrospective studies [9-11].

In the ARISTOTLE study, including 18,201 patients, 540 under went cardioversion. During the 30-day follow-up period, no thrombo embolic event was observed and the death rate did not differ between patients receiving apixaban and those receiving warfarin [12].

2.3. Place of Trans-esophageal Echography (TOE)

According to the recommendations of the European Heart Rhythm Association (EHRA) published in April 2013 updated in 2015 [8]: It's explained that in the absence of monitoring of the level of coagulation in the previous weeks, it is necessary to evaluate the compliance by asking the patient. It is clear that, if compliance is good, cardioversion can be safely performed (Figure 3). However, a trans-esophageal echography could be performed if a doubt about compliance exists.

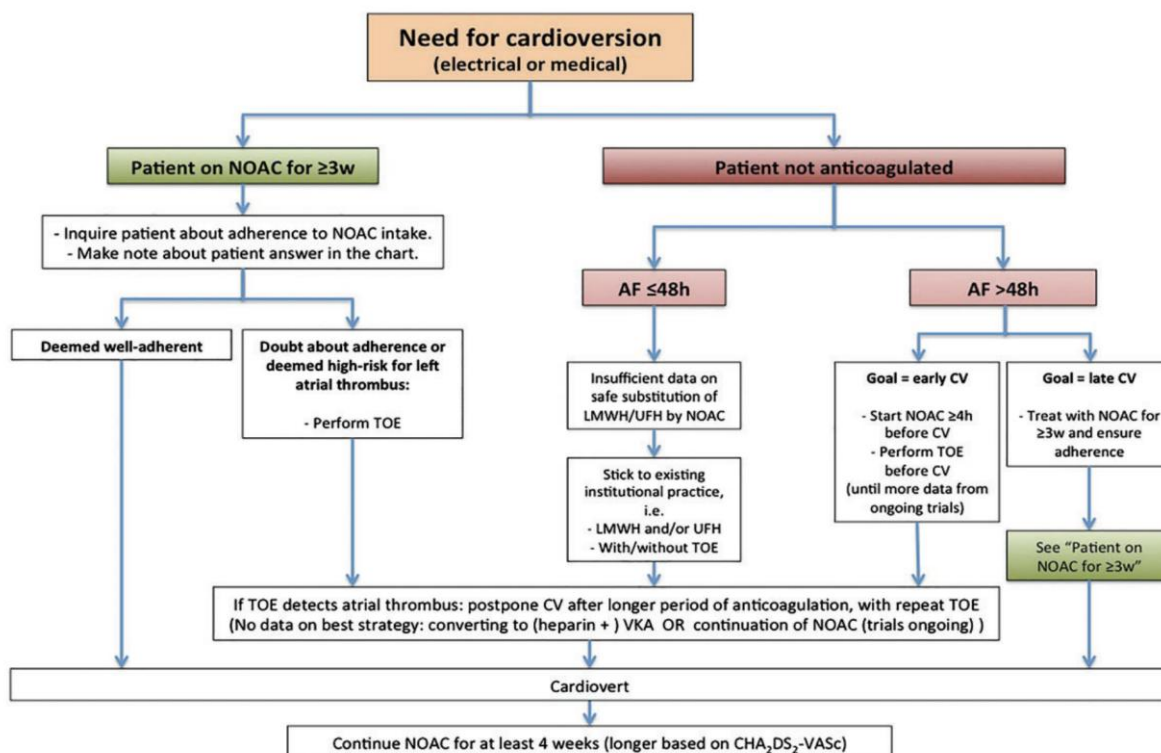


Figure 3 : Cardioversion work-flow in AF patients treated with NOAC, depending on the duration of the arrhythmia and prior anticoagulation [13].

2.4. Dose of apixaban

In the prevention of stroke and system icembolism in patients with non-valvular atrial fibrillation, the recommended dose of apixaban is two oral doses of 5 mg daily. A dosage adjustment of 5 mg × 2 / day to 2.5 mg twice daily is proposed when at least two of the following three risk factors are present: serum creatinine ≥ 15 mg / L, or age ≥ 80 years or weight body weight ≤ 60 kg [14].

CONCLUSION

Even if this case shows a hierarchy of complementary examinations according to the recommendations of the EHRA, the occurrence of thromboembolic events after cardioversion of a AF under well managed anti thrombotic treatment (apixaban in this case) can not be avoided. A systematic transesophage ultrasound should be discussed in this case and further studies are needed for either flutter ablations or cardioversions under direct oral anticoagulants.

REFERENCES

1. Hagg L, Johansson C, Jansson JH, Johansson L. External validity of the ARISTOTLE trial in real-life atrial fibrillation patients. *Cardiovasc Ther* 2014;32:214—8.
2. Daily Med, Current Medication Information, Rivaroxaban, <http://dailymed.nlm.nih.gov/dailymed>.
3. Daily Med, Current Medication Information, Apixaban <http://dailymed.nlm.nih.gov/dailymed>
4. Graff J, Harder S. Anticoagulant therapy with the oral direct factor Xa inhibitors rivaroxaban, apixaban and edoxaban and the thrombin inhibitor dabigatran etexilate in patients with hepatic impairment. *Clin Pharmacokinet* 2013,4 :243-54.
5. Daily Med, Current Medication Information, Dabigatran Etexilate Mesylate, <http://dailymed.nlm.nih.gov/dailymed>
6. Jan Václavík , Dabigatran antidote idarucizumab has come to clinical practice, *cor et vasa* 58 (2016) e1—e3
7. Kirchhof P, Benussi S, Kotecha D, et al. 2016 ESC Guidelines for the management of atrial fibrillation developed in collaboration with EACTS. *Eur Heart J* 2016; 37: 2893-962.
8. Granger CB, Alexander JH, McMurray JJ, Lopes RD, Hylek EM, Hanna M, et al. Apixaban versus warfarin in patients with atrial fibrillation. *N Engl J Med* 2011;365:981—92.
9. Arnold AZ, Mick MJ, Mazurek RP, Loop FD, Trohman RG. Role of prophylactic anticoagulation for direct current cardioversion in patients with atrial fibrillation or atrial flutter. *J Am Coll Cardiol* 1992;19:851-5.
10. Bjerkelund CJ, Orning OM. The efficacy of anticoagulant therapy in preventing embolism related to DC electrical conversion of atrial fibrillation. *Am J Cardiol* 1969;23:208-16.
11. Roy D, Marchand E, Gagné P, Chabot M, Cartier R. Usefulness of anticoagulant therapy in the prevention of embolic complications of atrial fibrillation. *Am Heart J* 1986;112:1039-43.
12. Flaker G, Lopes RD, Al-Khatib SM, Hermosillo AG, Hohnloser SH, Tinga B et al. Efficacy and safety of apixaban in patients following cardioversion for atrial fibrillation: insights from the ARISTOTLE trial. *J Am Coll Cardiol* 2014;63:1082-7.
13. Heidbuchel H, Verhamme P, Alings M, et al. EHRA updated practical guide on the use of new oral anticoagulants in patients with non-valvular atrial fibrillation, *Europace*. 2015 Oct; 17(10): 146-507
14. P. Albaladejo , D. Deplanque et al Bon usage d’apixaban : que retenir pour la pratique, *Journal des Maladies Vasculaires* Volume 39, Issue 6, December 2014, Pages 409-425.