

## A Prospective Analysis of Outcome in Conversion of External Fixators to Internal Fixators in Open Fractures of lower Limbs

Dr. L. Prasanna Kumar<sup>1</sup>, Dr. Phanikumar Bommavarapu<sup>2</sup>

<sup>1,2</sup>Department Of Orthopaedics, Rajiv Gandhi Institute Of Medical Sciences, Srikakulam, A.P

### ARTICLE INFO

Published Online:  
04 October 2018

### ABSTRACT

Open fractures occur as a result of great violence. Hence they are associated with considerable damage to the soft tissue envelope due to dissipation of the energy, displacement and comminution of long fragments. Secondary to this, there is local disruption of blood supply which results in more necrotic tissues. This impedes new angiogenesis as well as decreases the viability of the mesenchyme cells. Because of the severe violence, this fracture may be of compound nature. This leads to even more necrosis and by predisposing to infection, it further increases the risk of non-union. These high velocity injuries majority were associated with bone loss. These fractures require staged reconstruction, it further increases the risk of nonunion. Some surgeons use external fixation as a primary treatment until the soft tissues have healed and then employ another technique to secure union. Theoretically, the biomechanical and biological advantages of reamed intramedullary nailing would be expected to give good results, but the method has hazards, in particular infection. We therefore performed a prospective study to analyse the outcome of conversion to internal fixators in open fractures of lower limbs.

Corresponding Author:  
**Dr. Phanikumar  
Bommavarapu**

### INTRODUCTION

Open Injuries are usually high energy injuries and are frequently associated with life threatening polytrauma. Due to complexity of these injuries and their management, they have received significant attention; with most of this attention being directed at definitive treatment after arrival to an emergency department<sup>1</sup>. The skin is the main mechanical barrier to infection and the wound caused by an open fracture is mainly contaminated by the flora on the skin or in the environment. Devitalized soft tissues are an ideal medium for the proliferation of bacteria and the risk of infection is very high unless early treatment is implemented, including debridement, treatment with antibiotics and fixation. The principles of treatment of open injuries have gradually evolved over the centuries and especially from the experience of treating war injuries. Tscherne has grouped the developments into four eras of life preservation, limb preservation, infection prevention and functional restoration<sup>2</sup>. The problem of contamination was recognized even in the 16th century by Ambroise Pare who emphasized the need of cleaning the wounds of all foreign matter and necrotic tissue and leaving the wound open<sup>3</sup>. The term 'debridement' was coined by Desault in the 18th century as a procedure that involved extension of the wounds and clearing it of all

necrotic and contaminated tissue<sup>4</sup>. In the absence of antibiotics and aseptic surgical techniques, the incidence of mortality and amputation following infection was very high. 'Lose a Limb to save a Life' was an accepted dictum of management as gross infection of open injuries often leads to gangrene, septicemia and death.

The incidence of open tibial fractures has increased because of motor vehicle accidents. The annual incidence of open fractures of long bones has been estimated to be 11.5 per 100 000<sup>6</sup> persons with 40% occurring in the lower limb, commonly at the tibial diaphysis<sup>7</sup>. The subcutaneous position of the bone, limited soft tissue envelope and vascular supply make tibial fractures difficult to treat. Soft tissue damage is often the most important component of the injury, frequently dictating treatment. Using modern techniques, particularly myocutaneous flap coverage of large soft tissue defects, many more injured limbs that would previously have been amputated are being salvaged. The tibial shaft is more prone to open fractures than any other long bone of the human skeleton. Epidemiological studies have shown that open fractures comprise 23.5% of all tibial shaft fractures. The lack of muscular protection along the anteromedial aspect of the tibia and poor blood supply predispose open tibial fractures to certain complications. They present with a

10– 20-fold increased risk of developing infection than open fractures in other anatomical areas, and a non-union rate as high as 28% has been reported in the literature. Administration of intravenous broad-spectrum antibiotics, meticulous wound debridement, operative stabilization of the skeletal injury and early soft tissue coverage of the open wound are all part of the therapeutic protocols. Despite the general consensus supporting early skeletal stabilization, the optimal method of achieving osseous stability still remains a topic of controversy. External fixators have been widely used as they offer versatility, ease of application with minimum operative trauma, access to the wound and usually no interference with free joint movement. However, they were also associated with high rates of pin-loosening, mal-union and non-union.

Reamed intramedullary nails have few advocates, especially for severe Open Tibial Shaft Fractures due to the damage of the endosteal blood supply during the reaming process. The use of unreamed intramedullary nails has been associated with acceptable infection rates, apparently due to less interference with endosteal circulation, but a high rate of hardware failure has been reported in several studies. The use of plates and screws has been discouraged due to the potential damage to the periosteal blood supply during soft tissue stripping, and the increased risk for septic complications. The development of new biological techniques and implants have revived the interest towards open reduction and plate fixation. Increasingly focus is shifting to function as an outcome measure in orthopaedics. Understanding factors that influence ultimate function can be valuable in determining treatment options and properly informing patients of prognosis.

To help to control the risk of infection, nailing can be delayed for a ‘safety interval’ after removal of the fixator. Conversion to internal fixation, when needed must be performed when there are no contraindications. Definitive internal fixation either by an interlocking nail or a plate is ideally performed before the stage of definitive soft tissue cover<sup>8</sup>. Once a flap is performed, conversion has to be postponed to accommodate the flap settling time which may be between 3-4 weeks. There is a high chance of colonization of bacteria through the pin tracts at this time<sup>9</sup>. In a meta-analysis conversion of external fixator within 28 days resulted in a reduced rate of infection of only 3.7% compared to 22% when performed later<sup>10</sup>. In late conversions, an interval time of 10-14 days between removal and internal fixation, where the limb is splinted in a plaster has also been advised.

Debridement should be done as soon as possible after injury and the traditional teaching was that it preferably be completed within six hours. The aim was to prevent contamination from becoming infection and early debridement will prevent colonization of the bacteria within

the tissues. The basis of the six hour rule was animal studies where a threshold of 10<sup>5</sup> organisms was found to be critical to establish infection and this limit was achieved in 5.17 hours<sup>11</sup>. This led to the practice of debridement to be done even in the middle of the night when experienced work force was not available. The six hour rule has been challenged by some studies<sup>12</sup>. Current literature suggests no obvious advantage in performing debridement within 12 hours compared to debridement performed between 6 and 24 hours after injury<sup>12</sup>. The effect of delays > 24 hours is however not yet clear<sup>13</sup>. While debridement must be done as soon as safely possible, the thoroughness of debridement seems to be more important than timing of debridement. In addition there other local and systemic factors that influence infection and wound healing.

## MATERIALS AND METHODS

This is a prospective study conducted with inclusion of patients admitted during the period of September 2017 to July 2018. This study included patients of both sex and age group between 10-85 year, admitted in the our Rajiv Gandhi institute of medical sciences with open lower limb long bone fractures in whom an external fixator is applied as a temporary method of fixation followed by conversion to internal fixation in the form of intra medullary implant or plate. All cases were followed for a period of minimum of 11 months. Our institutional review board approval taken before the study. Consent has been taken from each patient. All preoperative, intraoperative and postoperative details were recorded from the case sheets and then entered into a Microsoft Excel spreadsheet. All details were recorded in a special proforma. Final outcome was compared with results in available latest literature and statistical analysis made by applying tests of significance – student t test and Pearson chi square test. The study includes age between 10 – 85 yr with open femur or tibia fracture and external fixator converted to internal fixator and we excluded the Patients with bone loss > 4 cms treated with LRS and bone transport. Open fractures treated with definitive external fixators. On admission general condition of the patient was assessed with regards to hypovolemia and associated orthopedic or other systemic injuries and resuscitative measures taken accordingly. All patients received analgesics in the form of I.M injections, anti-Tetanus immunoglobulin, and antibiotics intravenously.

Patients with Type 1 and 2 Gustillo- Anderson wounds received 2nd generation cephalosporin and those with Type 3 wounds received 2nd generation cephalosporin and inj. Amikacin 1gm IV for 2 days. A thorough clinical examination was performed including detailed history relating to age, sex, occupation, mode of injury, past and associated medical illness. Routine investigations were done

## “A Prospective Analysis of Outcome in Conversion of External Fixators to Internal Fixators in Open Fractures of Lower Limbs”

in all patients. All patients were assessed radio graphically to assess for any injuries. X rays were taken in two planes antero-posterior and lateral views. Importance is given to serious injuries like head injuries. Decisions for immediate definitive or staged fixation was based on GHOISS , the interval since injury, the degree of contamination of the wound, the extent of injury to the soft tissues, and the degree of associated vital organ injuries, the consulting surgeon. Intravenous antibiotic treatment with a 2 nd generation cephalosporin for Gustilo type I and II fractures with the addition of an aminoglycoside (usually amikacin 1g iv for 2 days) for type-III fractures was begun in the emergency room, and continued for 48 hours after the initial procedure. After the patient was resuscitated and all required emergency surgical procedures were completed, the open wound was irrigated and debrided. Irrigations were performed by using low-pressure bulb syringes for type I and II fractures, and performed by using high-pressure pulsating water jet devices for type III fractures

During that period, 130 patients were collected who underwent initial external fixation of 133 fractures of the femur and tibia .Of these 13 patients lost followup and 2 patients have 2 month follow up are deleted from the study . The remaining 113 patients (116 fractures) were treated by conversion of the external fixation to intramedullary nail or plate stabilization. The minimum duration of follow-up was 11 months , maximum one and half years; The age of the 112 male patients and 3 female patients in the study averaged thirty-nine years.51 were open femoral fractures , 65 were open tibial fractures .

### RESULTS

The duration of external fixation averaged twenty eight days (range, two to one hundred twenty days).there was 29 ( twenty nine ) fractures in which pin tracts got infected. they were treated with antibiotics based on culture and sensitivity obtained from the pin tract discharge . In all the other 87 situations with no evidence of pin-loosening or pin-track infection before the external fixator was removed, conversion from external fixation to intramedullary nailing or plating was performed as a one-stage procedure (that is, under the same anesthesia but with separate preparation and draping procedures).

External fixation was converted to Interlocking intramedullary nail or plate in all patients under fluoroscopic control. Excision of pin tracts with washout was done in all the patients. 62 ( 53.4 % ) fractures underwent statically locked reamed interlocking nail using the largest possible nail size. Bone grafting was used in 43 ( 37.06 % ) fractures .In 63 patients ( 54.3 % ) skin was closed primarily with skin suturing, 31 underwent flap procedure, 22 underwent secondary skin grafting.Patients were ambulated on the second postoperative day and discharged with instructions to use two crutches/walker and to avoid bearing weight on the extremity. Of the 116 fractures available for followup ,91 ( 78 .4 percent) healed within seven months without complications. removal of distal interlocking screws was done at four months as a method of dynamization in five fractures ( five patients ) and the fracture healed uneventfully within six months after that procedure.

### DEMOGRAPHIC DATA: AGE DISTRIBUTION

MEAN AGE IN THE STUDY- 39 years

Age group	number	percentage
<b>16 – 25 years</b>	<b>17</b>	<b>16%</b>
26 – 35 years	30	26%
36 – 45 years	30	26%
46 – 55 years	21	19%
56 – 65 years	15	13%

### SEX DISTRIBUTION:

Sex	Number	Percentage
Male	110	97.3%
Female	3	2.7%

### SIDE OF INVOLVEMENT

Right	77
Left	37
Bilateral	1

“A Prospective Analysis of Outcome in Conversion of External Fixators to Internal Fixators in Open Fractures of Lower Limbs”

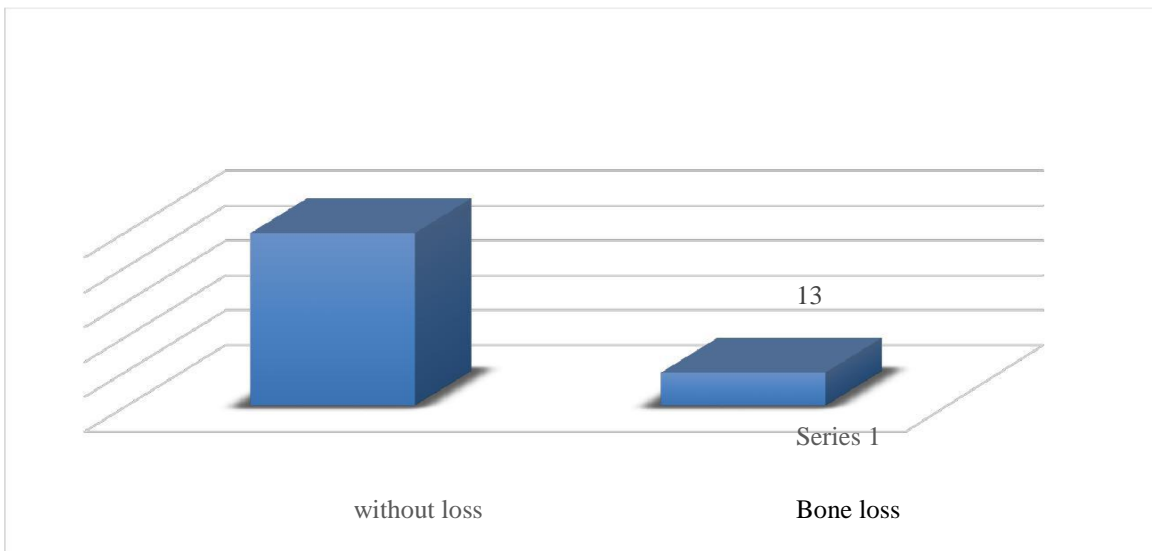
**DISTRIBUTION OF INJURIES BASED ON GHOISS :**

0												
	4	5	6	7	8	9	10	11	12	13	14	
Series 1	2	8	19	7	11	23	18	1	8	4	0	

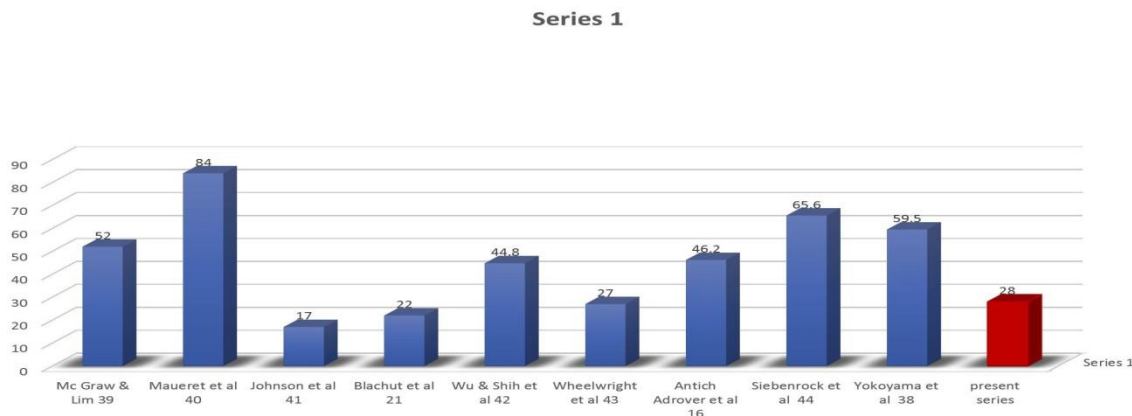
**MODE OF INJURY :** Mode of injury were as follows with RTA dominating the injury types .

Mode of injury	Number	Percentage
RTA	104	92.03 %
Fall from height	6	5.30%
Fall of weight	3	2.65%

**BONE LOSS :**



COMPARED TO OLD REPORTS OF SECONDARY INTERNAL FIXATION AFTER EXTERNAL FIXATION FOR OPEN FRACTURES:DURATION OF EXTERNAL FIXATOR :

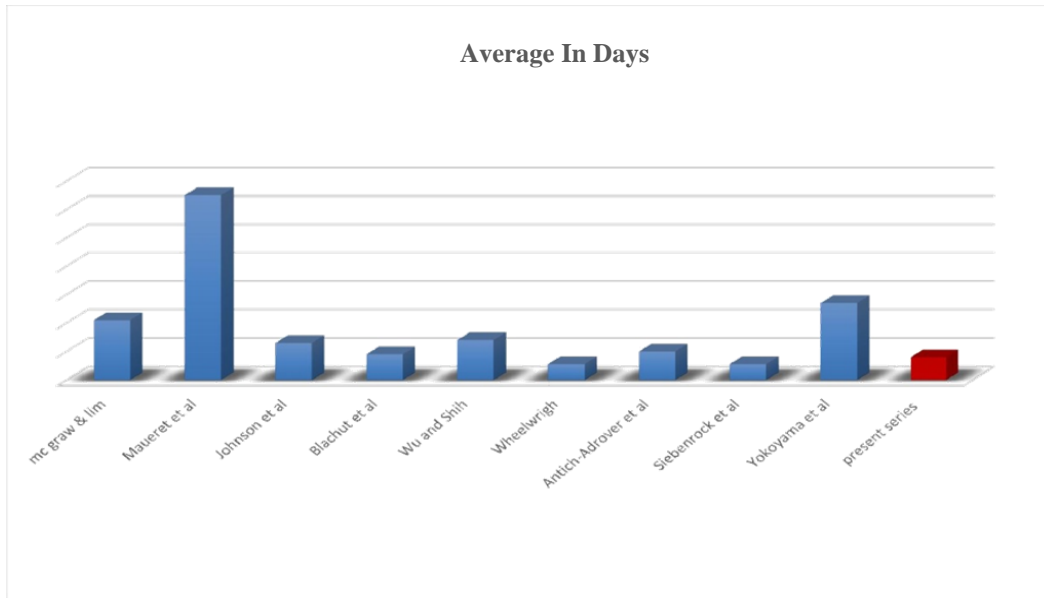


## “A Prospective Analysis of Outcome in Conversion of External Fixators to Internal Fixators in Open Fractures of Lower Limbs”

24 of the 116 open femur and tibia fractures developed infections( superficial 10 , deep 14 ). The Infection occurrence with GHOISS appears to be nearly statistically significant ( p = 0.06). The relationship between Infection and union with the following factors: age, debridement time, duration of external fixation, interval until skin closure and

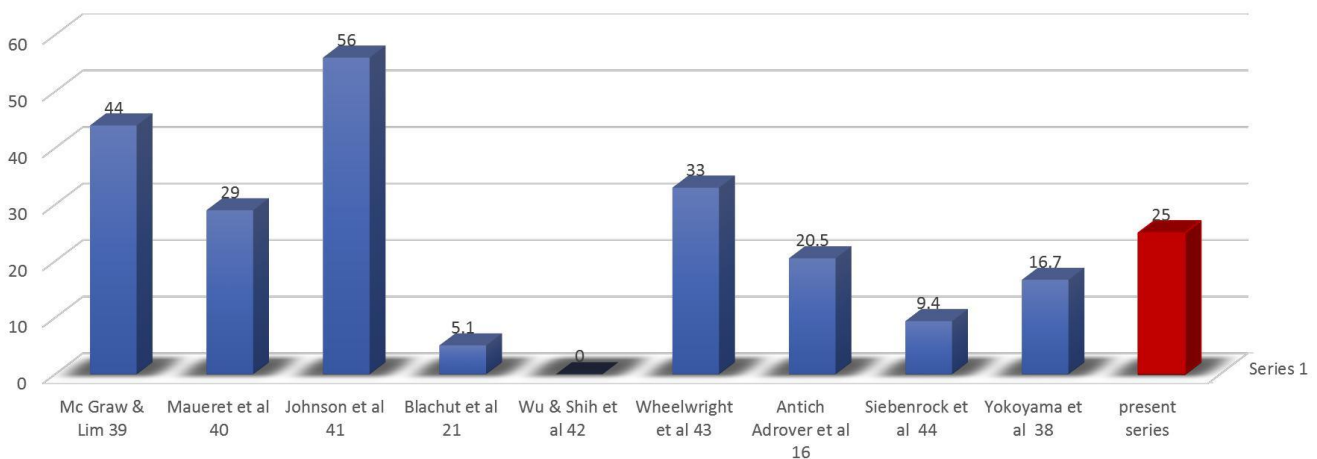
existence of pin tract infection was not statistically significant. The interval between external fixator to internal fixator and the GHOISS was a nearly significant factor-affecting occurrence of deep infection and union on this analysis ( p = 0.06). The statistical results are summarized as follows :

The safe Interval period in days as follows :



Pin site infection in percentage :

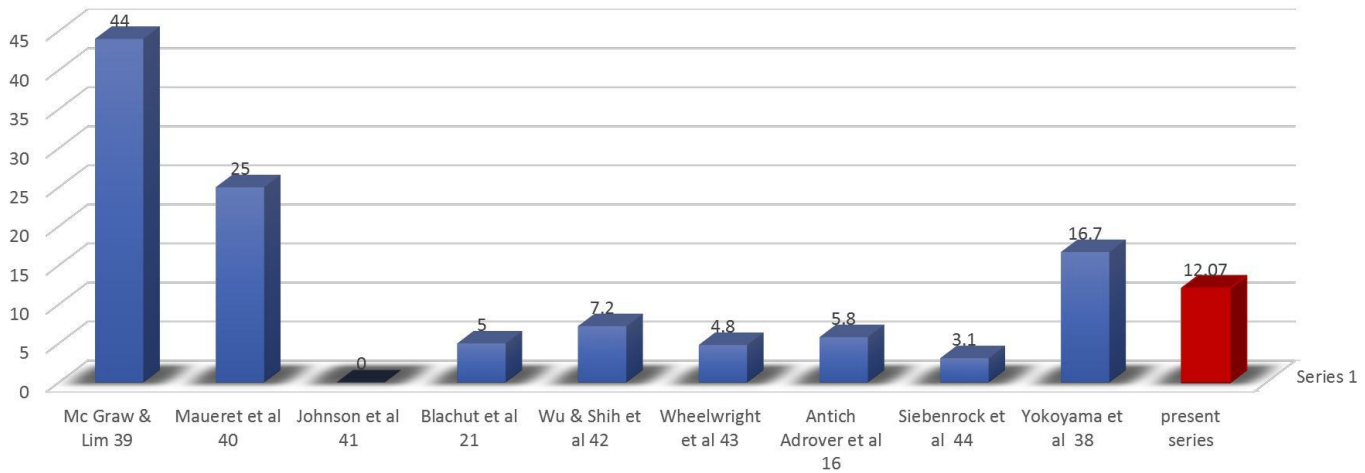
### Pin track infection Rate



“A Prospective Analysis of Outcome in Conversion of External Fixators to Internal Fixators in Open Fractures of Lower Limbs”

Deep Infection rate :

**Deep infection Rate**



Infection rate and p values by univariate analysis :

Factor			P – value
Gender	Male	110	0.846
	Female	3	
G A score	type 2	1/7	--
	Type 3a	5/26	
	Type 3b	18/ 57	
GHOISS	group 4-7	4/ 36	0.093
	8-11	17/68	
	12 & above	3 / 12	
Injury antibiotic interval	< 6 hours	infection 9/45	0.913
	> 6 hours	infection 15/71	
Injury debridement interval	< 6 hours	infection 4/28	0.286
	> 6 hours	infection 20/88	
Bone loss < 3cms		13 /116	0.433

“A Prospective Analysis of Outcome in Conversion of External Fixators to Internal Fixators in Open Fractures of Lower Limbs”


Pin tract infection		29/116		<u>0.081</u>
External fixator <3wks	infection < 3 weeks	12/62		
	> 3 weeks	12 /54	0.672	
Interval period < 2wks	< 2 weeks	15/90		
	> 2 weeks	9 /26		0.06

Soft tissue closure < 24 hours 5 infections / 56 closures < 24 hours

Union and P- values by univariate analysis :

Factor	Range	P- value		
Age	non union	18 to 63 ( avg 41 yrs)		
	Union 13 to 82	( avg 39.1 yrs )	<u>0.177</u>	_____
G A score	non union	type i 1/7		
	Type ii	2/23		
	Type iiiia	4/26		
	Type iiib	10/57		
	Type iiic	1/3	--	
	GHOISS	group 4 to 7	4/ 36	
	8 to 11	12/68		
	12 & above	3/ 12	<u>0.062</u>	_____
Injury antibiotic interval < 6 hours	< 6 hours	nonunions 9 / 45		
	> 6 hours	nonunions 10 / 71	0.244	_____
Injury debridement interval < 6 hours	< 6 hours	nonunions 3/ 28		
	> 6 hours	nonunions 16/88	<u>0.266</u>	<span style="background-color: red; color: black; display: inline-block; width: 20px; height: 10px;"></span>

“A Prospective Analysis of Outcome in Conversion of External Fixators to Internal Fixators in Open Fractures of Lower Limbs”

Bone loss < 3cms	13 / 116	<u>0.190</u>	
Pin tract infection	29 / 116	<u>0.109</u>	

39

External fixator <3wks	nonunion < 3 weeks	10/62	
	> 3 weeks	9/54	0.909
Interval period < 2wks	nonunion < 2weeks	15/90	
	> 2 weeks	4/ 26	0.720

\*\*Underlined: p < 0.5 in analysis

Complications : Nonunion : 19 cases underwent nonunion .All the cases underwent bonegrafting +/- augmentation plating later .

Implant related problems : One patient had screw breakage . Anterior knee pain: in our study 4 patients developed anterior knee pain . It is most commonly reported after intramedullary nailing.

Fat embolism: 1 patient developed fat embolism syndrome treated with supportive care and steroids

**DISCUSSION**

There are many advantages of early fracture stabilization in multiply injured patients: They help in early patient mobility, improves pulmonary toilet, decreases pain and thus the need for analgesics , decreases SIRS (inflammatory mediator response), and decreases chances of thromboembolism. Early stabilization of femoral fractures has been shown to decrease morbidity and mortality<sup>17</sup>..But A badly injured patient with open injury who remains physiologically unstable can tolerate only the shortest surgical procedure for fixation of a fracture of the femur and tibia like application of temporary external fixator .External fixation followed by delayed undreamed interlocking nailing minimises the disadvantages of external fixation alone (bad cosmesis, frequent pin trouble, risk of fracture through the pin tract, risks of malunion, delayed union, and nonunion, and non-compliance of patients in pin tract care affecting fixator durability).<sup>18</sup>

This type of fixation is often used for severe open tibial fractures, especially for patients with polytrauma, as a ‘damage control’ method. It is a useful and safe solution for open lower limb fractures in severely damaged multi-trauma patients<sup>19</sup>.However, it risks having intramedullary infection as a result of: pin-site infection, prolonged external fixation, the short safety interval between removal of the external fixator and intramedullary nailing, reamed procedure in secondary nailing, noncurettage of pin sites at the removal of the external fixator, and poorly vascularised soft tissue coverage.It is believed that conversion to interlocking intramedullary nailing before the development of complications related to long-term external fixation would be a good alternative for the management of fractures of the femur in multiply injured patients. Average time to union in our study ( staged fixation) was 11 months. This union time was more due to severe comminution of fracture and associated soft tissue loss with staged reconstruction Malunion rate in open reduction and internal fixation methods, exact alignment under direct vision is always an inherent advantage compared with external fixation. Malunion rate of intramedullary nailing methods is also controlled at a fairly acceptable level compared with other therapies The external fixation methods, although having easy application and lower cost, must overcome the difficulties in accurate anatomical reduction and anomaly prevention with a limited exposure of the wound site. Once the healing procedure begins, the final bony healing can be



## “A Prospective Analysis of Outcome in Conversion of External Fixators to Internal Fixators in Open Fractures of Lower Limbs”

achieved in both groups despite the alignment condition, suggesting that the bone healing could not discriminate

between right and wrong for the alignment pattern, and the importance of primary achievement of a good alignment.

1 ) In our study as the interval period relation with infection came near to being significant ( p value 0.06) , its role in causing infection cannot be ruled out.

2 ) RIMS hospital open injury score :

Score	Number	Infections
4 to 7	36	4
8 to 11	68	17
12 & above	12	3

Though statistically the p value came as 0.092, there is an increasing trend of infection as the Ganga hospital open injury score rises .

Injury debridement interval ( IDA ) < 6 hours :

IDA	Absolute number	%( infection and nonunion)
< 6hours	4 – infected & 24 – not infected 3 nonunion , 25 united	14 % and 10.34%
>6 hours	20-- infected & 68 – not infected 16 nonunion, 72 united	23 % and 18.18%

The relation of injury debridement interval with infection came to 0.28. But as the time interval to debridement is increased , the percentage of infection raises to 23 % from 14 % and nonunion rate increases from 10.34 % to 18.18 %

Injury antibiotic interval < 6 hours :

Injury antibiotic interval	Number	% ( infection & nonunion )
< 6 hours	9 infected & 36 noninfected 9 nonunion & 36 united	20 % and 20 %
> 6 hours	15 infected & 56 noninfected 10 nonunion & 61 united	21.12 % and 16.39 %

4 ) interval period between external fixator removal to internal fixation :

The conversion with the interval < 2 weeks is associated with higher infections and it is nearly significant ( p value 0.06 ) , the conversion is advised to be done only after all the medullary cavity and the bone is treated for the infecting bacteria .

5 ) Relation between Nonunion with GHOISS

4 – 7 GHOISS	4/ 36 infections	1 : 9
8 - 11 GHOISS	12 / 68 infections	1: 5
12 & above	3/ 12 infections	1: 4

As the score goes on increasing , the infection rate is increasing and it is statistically nearly significant. ( p = 0.06 ) .

6 ) The soft tissue closure < 24 hours has significant correlation to infection rate with p value of 0.02 .

### CONCLUSIONS

RIMS hospital score has an effect on the union rate and the infection rate. The 2 week interval between external fixator removal to internal fixation is recommended to decrease the chances of infection Other factors described like antibiotic

administration within 6 hours , injury debridement needs randomized controlled larger studies to look for significance  
Recommendations : : Timely admission to a definitive trauma treatment center has a significant beneficial influence on the incidence of infection after open high-

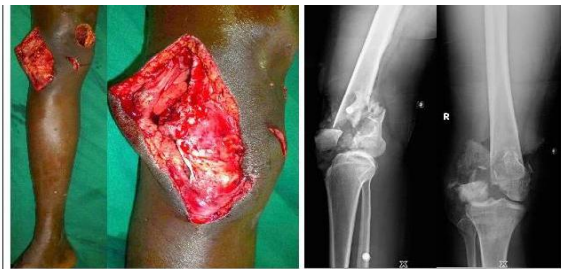“A Prospective Analysis of Outcome in Conversion of External Fixators to Internal Fixators in Open Fractures of Lower Limbs”

energy lower extremity trauma. It is advised to have the soft tissue cover in less than 24 hours to decrease the chances of infection. It is better to wait for granulation at the pin sites to appear before secondary fixation, after at least a delay averaging seven days. There is little significance for chances

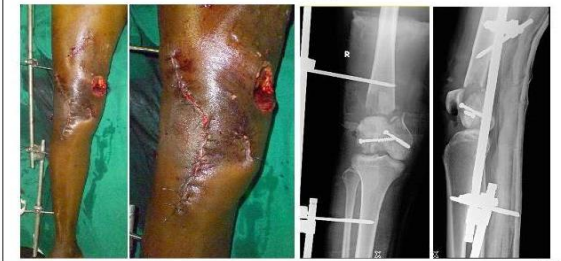of infection in relation to interval between the conversion of external fixator to internal fixator. GHOISS can be used to prognosticate and in planning the management of open injuries

Case 1

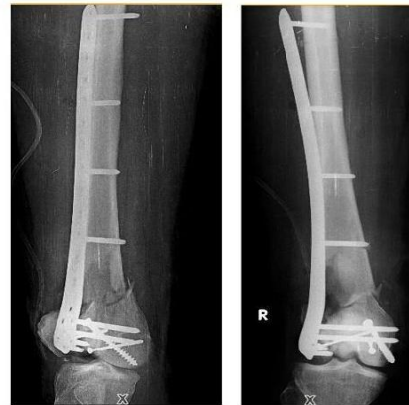pre op



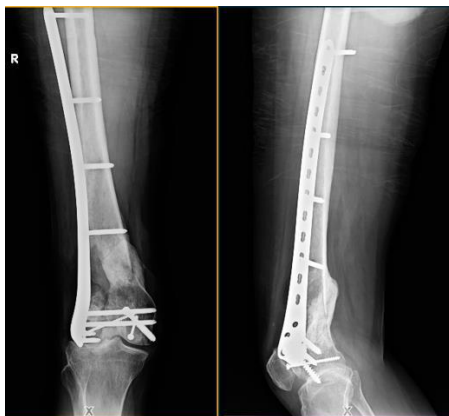Post-op



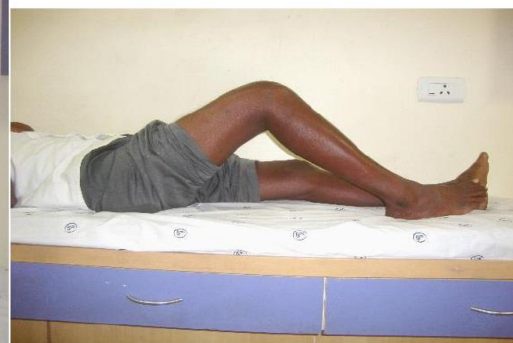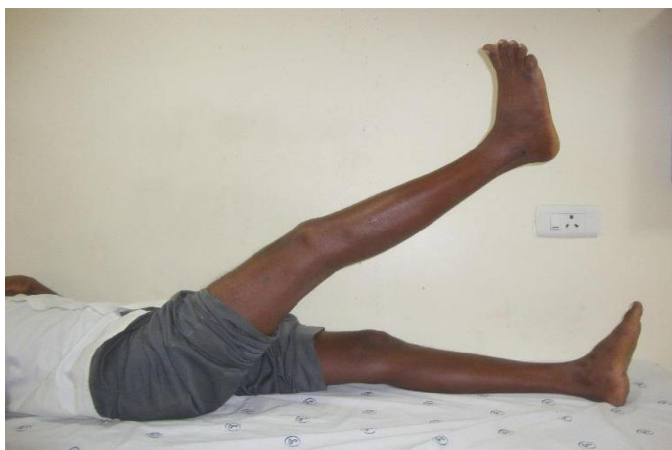4-C1



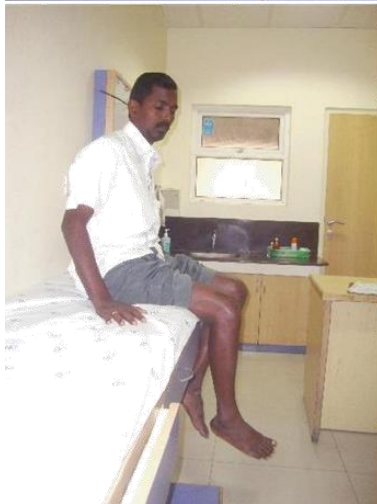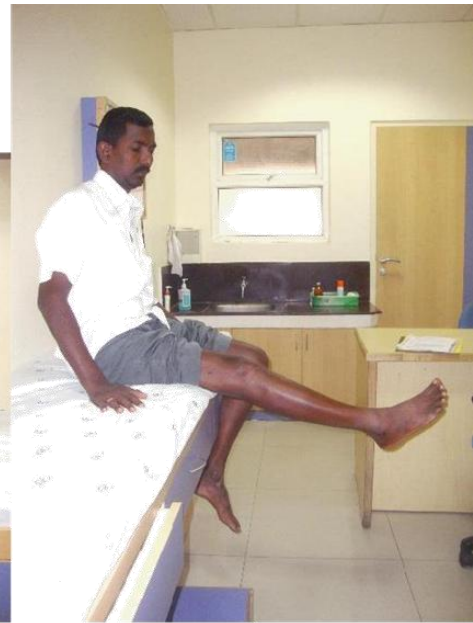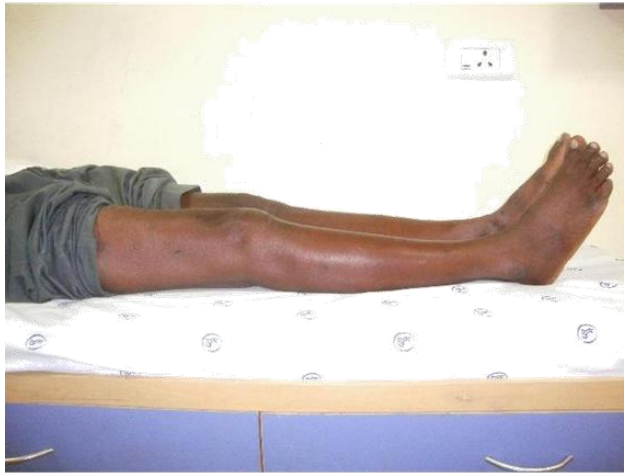4-C1



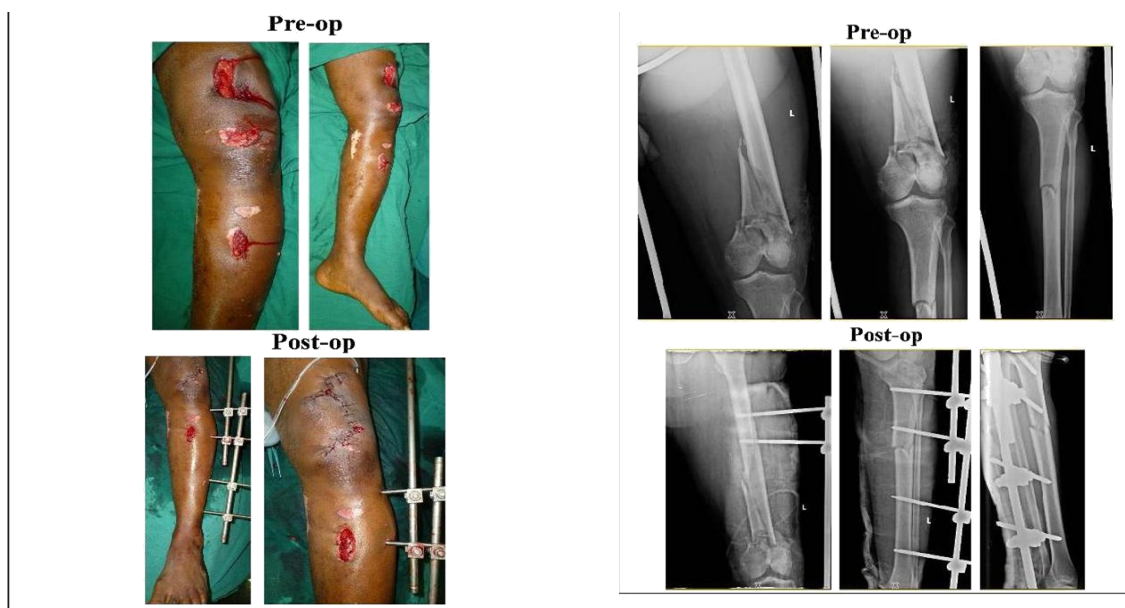
38 year old man with a type IIIB femoral fracture at the distal site of the knee. The femoral fracture was stabilized by external fixator (a). A skin defect was covered primarily. Femoral locking plate was introduced after removal of external fixator (b). The fracture healing occurred in 12 months with no infection (c).



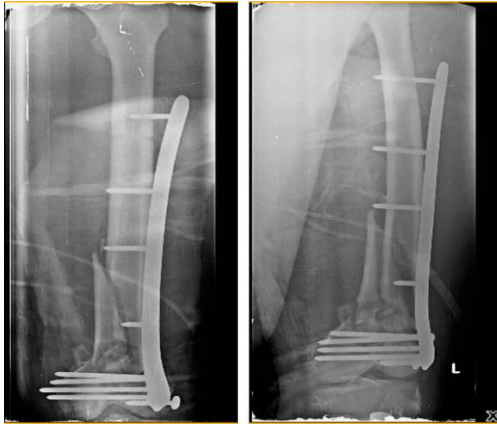
“A Prospective Analysis of Outcome in Conversion of External Fixators to Internal Fixators in Open Fractures of Lower Limbs”



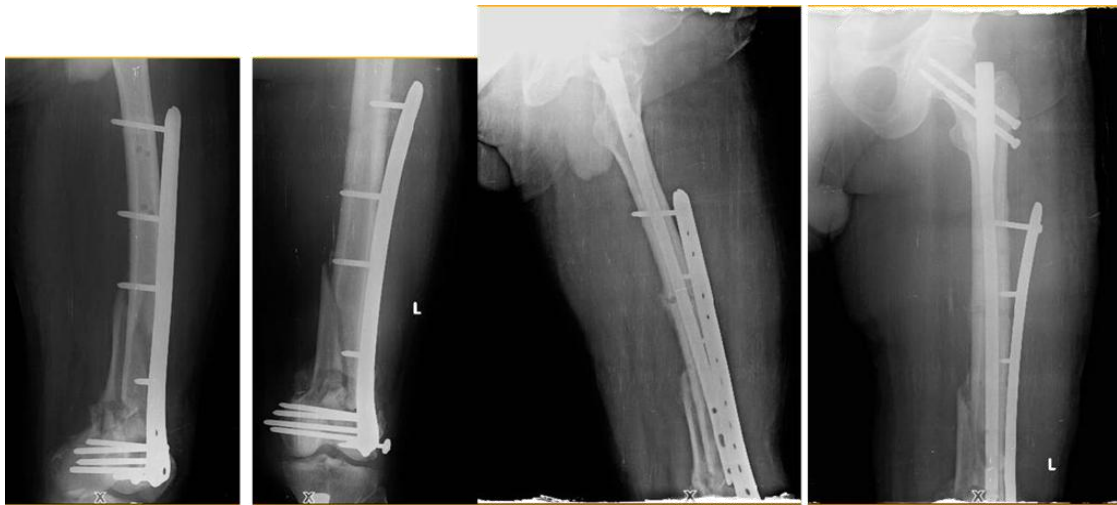Case 2



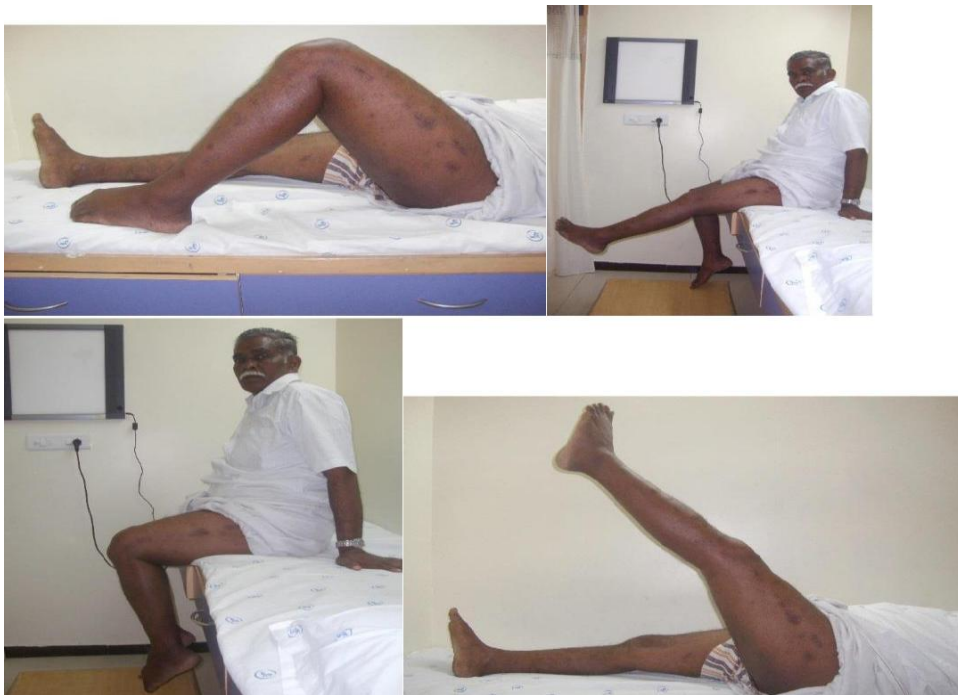“A Prospective Analysis of Outcome in Conversion of External Fixators to Internal Fixators in Open Fractures of Lower Limbs”



LEFT GRADE 3B SUPRACONDYLAR COMMUNUTED FEMUR FRACTURE, LEFT GRADE I TRANSVERSE TIBIA FRACTURE



FRACTURE OF LEFT FEMORAL SHAFT AT NONUNION SITE ... treated with EXCHANGE OF PROXIMAL LOCKING SCREWS AND AFN FIXATION OF LEFT FEMUR



Clinical photos after union of femur fracture

“A Prospective Analysis of Outcome in Conversion of External Fixators to Internal Fixators in Open Fractures of Lower Limbs”

**REFERENCES**

1. Tscherne H. Management of open fractures 1983; 162: 10-32.
2. Kocher MS. Early limb salvage: open tibia fractures of Ambroise Pare (1510-1590) and Percivall Pott (1714-1789). *World journal of surgery* 1997; 21: 116-22.
3. Guthrie HC and Clasper JC. Historical origins and current concepts of wound debridement. *Journal of the Royal Army Medical Corps* 2011; 157: 130-2
4. Giannoudis PV1, Harwood PJ Long-term quality of life in trauma patients following the full spectrum of tibial injury (fasciotomy, closed fracture, grade IIIB/IIIC open fracture and amputation). 2009 injury
5. Howard M, Court-Brown CM. Epidemiology and management of open fractures of the lower limb. *Br J Hosp Med* 1997;57:582-7.
6. Rajasekaran S and Sabapathy SR. A philosophy of care of open injuries based on the Ganga hospital score. *Injury* 2007; 38: 137-46
7. Mc Graw J and et al. Treatment of open tibial shaft fractures, external fixation and secondary IM nails. *J. Bone joint surgery AM* 1988; 70: 900-911.
8. Bhandari M, Zlowodzki M, Tornetta P, 3rd, Schmidt A, and Templeman DC. Intramedullary nailing following external fixation in femoral and tibial shaft fractures. *Journal of orthopaedic trauma* 2005; 19: 140-4.
9. Robson MC, Duke WF, and Krizek TJ. Rapid bacterial screening in the treatment of civilian wounds. *The Journal of surgical research* 1973; 14: 426-30.
10. Crowley DJ, Kanakaris NK, and Giannoudis PV. Debridement and wound closure of open fractures: the impact of the time factor on infection rates. *Injury* 2007; 38: 879-89.
11. Werner CM, Pierpont Y, and Pollak AN. The urgency of surgical debridement in the management of open fractures. *The Journal of the American Academy of Orthopaedic Surgeons* 2008; 16: 369-75.
12. Peter J. Nowotarski, Clifford H Turen .Conversion of External Fixation to Intramedullary Nailing for Fractures of the Shaft of the Femur in Multiply Injured Patients VOL. 82-A, NO. 6, JUNE 2000
13. Immediate interlocking nailing versus external fixation followed by delayed interlocking nailing for Gustilo type IIIB open tibial fractures HJ Park, M Uchino, K Nakamura, M Ueno, Y Kojima, M Itoman *Journal of Orthopaedic Surgery* 2007; 15(2):131-6
14. F. Lavini • E. Carità • C. Dall’Oca • R. Bortolazzi. Internal femoral osteosynthesis after external fixation in multiple-trauma patients. *Traum Limb Recon* (2007) 2:35–38
15. Treatment of Distal Femur and Proximal Tibia Fractures With External Fixation Followed by Planned Conversion to Internal Fixation . *J Trauma*. 2008;64 :736–739. Volume 64 ,Number 3
16. Conversion of external fixation to internal fixation in a non-acute, reconstructive setting: a case series T. Monni , F. F. Birkholtz. *Traum Limb Recon* (2013) 8:25–30