



# Ventricular Septal Rupture Complicating Acute Myocardial Infarction

*Nadia Loudiyi<sup>1</sup>, Siham Bellouize<sup>2</sup>, Najat Mouine<sup>3</sup>, Youssef El Bekkali<sup>4</sup>, El Mehdi Zbire<sup>5</sup>*

<sup>1,3,5</sup>Cardiology department of Mohammed V Military Hospital, Rabat, Morocco

<sup>2,4</sup>Cardiovascular surgery department of Mohammed V Military Hospital, Rabat, Morocco

**Abstract:** Ventricular septal rupture (VSR) is a rare but devastating complication after acute myocardial infarction (AMI). Its accompanied by a very high mortality rate (97% at 30 days of AMI) [1]. The prognosis is greatly improved by the surgical management. This is a retrospective study of 5 cases of VSR following AMI, operated over a two-year period, between November 2013 and December 2014, in the cardiovascular surgery department of the Mohamed V military hospital in Rabat . Clinical information and echocardiography data as well as surgical results, were collected from patient records. All our patients are male, with an average age of  $61.4 \pm 4.15$  years. Cardiovascular risk factors are dominated by sex at 100%, smoking; Age; diabetes and dyslipidemia at 60%; and obesity at 20%. Concerning the cardiovascular history: AMI <1 month at 100%, angioplasty at 40%, and thrombolysis at 20%. The functional signs are dominated by dyspnea stage III to IV of the NYHA, with angina pain. For the physical signs, all the patients were on cardiogenic shock, with systolic murmur over the precordium. At the ECG, there were necrosis sequelae with persistence of the ST elevation in 100% of the patients on extensive anterior territory (40%), antero-septo apical territory (40%) and circumferential territory (20%). The chest X-ray demonstrated a cardio thoracic index at  $0.55 \pm 0.09$  with signs of pulmonary edema in 40% of patients. In all patients, the echocardiography demonstrated muscle and apical VSR with an average diameter of 10 mm and restrictive in 80% of cases. The left ventricle is dilated in all patients (LVTDD at  $60.8 \text{ mm} \pm 4.86$ , LVTSD at  $50 \text{ mm} \pm 3.2$ ) with EF <40%. At coronary angiography, there was an 80% monotoncular lesion, and a 20% bitronuclear lesion. After stabilization by medical treatment, patients underwent VSR surgical closure, left ventricular aneurysm treatment in 2 patients, and coronary bypass surgery in one patient. The postoperative results were satisfactory in 60% of the cases, with a mortality of 40%. VSR is a rare and serious mechanical complication. The best treatment is based on surgery with a heavy morbidity and mortality. Hence the value of optimizing the management of the AMI.

## I. INTRODUCTION

The development of coronary units and the advent of early reperfusion have greatly reduced hospital mortality of ST Elevation Myocardial Infarction (STEMI).

Moreover, the reduction in reperfusion time and the generalization of urgent invasive management have further accentuated this reduction in the mortality rate from 10% to less than 5% over the last 15 years. [1]

Early mortality, which is nevertheless high, is consecutive either to severe left or right ventricular failure with refractory shock, or to mechanical complications, the main three being ventricular septal

rupture (VSR), cardiac free wall rupture and acute mitral insufficiency.

Ventricular septal rupture accounts for 10-15% of the mechanical complications of myocardial infarction [2], and occurs in 0.5% of cases in the acute phase [3], often resulting in sudden hemodynamic degradation.

Its diagnosis and treatment must be very early because in the absence of urgent medical-surgical management, the evolution is very serious and the mortality is high.

The aim of this study is to assess the various predictive factors in the development of ventricular septal rupture as well as its clinical manifestations, diagnostic methods, in particular echocardiography,



and the methods of medico- Urgent surgery, while reporting the results of our patients after surgical cure.

## II. MATERIALS AND METHODS

This is a retrospective study of 5 cases of ventricular septal rupture complicating acute myocardial infarction, operated over a two-year period, between November 2013 and the end of 2014 in the cardiovascular surgery department of the Mohamed V military hospital in Rabat.

Epidemiological, clinical, and para-clinical data as well as surgical and postoperative data were collected from patients' medical records.

## III. RESULTS

### A. Characteristics of the Population

The average age of our patients was 61.4 years  $\pm$  4.15 with extremes of 56 years to 63 years, all male.

Among our five patients, there are five cases of myocardial infarction dating from less than one month, two cases of coronary angioplasty (IVA) and one case of thrombolysis (at H2).

The cardiovascular risk factors are as follows:

- Gender: all patients are male 100%
- Age > 60 years for 3 patients, 60% and a mean age of 61.4  $\pm$  4.15
- Smoking in 5 patients 100%
- Diabetes found in 3 patients, 60%
- Arterial hypertension found in 5 patients, 100%
- Dyslipidemia for 3 patients, 60%
- Obesity concerns 1 patient or 20%

Thus, there is a clear predominance of the main cardiovascular risk factors: sex, age, tobacco, diabetes, hypertension and dyslipidemia.

### B. Clinical Data

The clinical picture was dominated by cardiogenic shock and stage IV dyspnea of the NYHA.

The 5 patients had a systolic murmur over the precordium, with crepitant rales at the two pulmonary fields.

All patients were in regular sinus rhythm (RRS), but in addition to the persistence of ST elevation, sequelae of

AMI were observed in Q-wave form of necrosis. This AMI is distributed as follows: Extended anterior territory: 2 cases, Antero-septo-apical territory: 2 cases, Circumferential territory: 1 case.

On the chest radiograph, the mean cardio thoracic index is 0.55  $\pm$  0.09 with extremes ranging from 0.47 to 0.70

In our patients, trans-thoracic echocardiography finds a muscular ventricular septal rupture with apical localisation, restrictive, with an average diameter of 10 mm

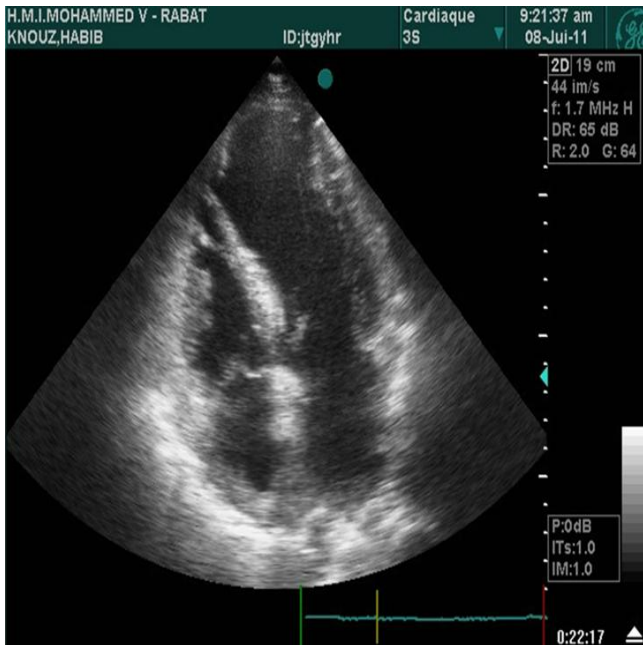
An aneurysm of the left ventricle (LV) of the anterior seat was found in 2 cases.

The LVEF was overall less than 40% with an average of 32.2%  $\pm$  4.32, with a telediastolic diameter of the LV at 60.80mm  $\pm$  4,86 and a telesystolic diameter of the LV at 50 mm  $\pm$  3, 20

The results of coronary angiography are summarized as follows: 4 patients, 80% were mono-truncular and one patient, 20% was bi-truncular and no tri-truncular were observed, thus a large predominance of monotonular lesions.

**Table 1 : Summary of Demographic and Clinical Data**

Settings	Number, average
Age	61,4 $\pm$ 4,15 ans
Sex (Male)	5 (100%)
Diabetes	3 (60%)
Arterial hypertension	0
Smoking	5 (100%)
dyslipidemia	3 (60%)
Angioplasty	2 (40%)
thrombolysis	1(20%)
AMI < 1 mois	5 (100%)
unstable angina	5(100%)
AMI Anterior	2 (40%)
AMI ASA	2 (40%)
AMI circumferential	1 (20%)
EF < 40%	5 (100%)
TDLVDVG	60,80 $\pm$ 4,86
TSLVDVG	50 $\pm$ 3,208
Aneurism VG	2 (40%)
Bitronculaire	1 (20%)
tritronculaire	0
Monotonculaire	4 (80%)



**Figure 1 :** Echocardiographic aspect of apical muscular VSR

### C. Surgical Data

Before surgery, all our patients were under medical treatment, often including a platelet antiaggregant, a beta blocker, an enzyme conversion inhibitor, and a statin.

**Intervention Delay:** Due to the hemodynamic state of the patients, they were operated in emergency by the admission and after putting in conditions. The anesthetic induction was carried out in a positive inotropic support and the use of mechanical circulatory support with intra-aortic balloon pump (IABP)

**Surgical procedure:** These patients were operated by the same team by stereotomy and under cardiopulmonary bypass (CPB). While myocardial protection was provided by a peripheral crystalloid cardioplegic perfusion repeated every 30 minutes, combined with moderate hypothermia at 32-34 °C.

**Surgical repair of VSR:** The 5 patients were operated according to the same surgical procedure: after longitudinal ventriculotomy in full necrotic tissue and parallel to the anterior inter ventricular sulcus. Exposure of the ventricular cavity discovers a VSR with friable bumps but always at a distance from the mitral pillars.

Closure of the VSR by a synthetic patch (Dacron) cut to measure and sewn by a crown of points trained in U of wire 2/0 (Ethibon).

Closure of the ventriculotomy ribs on two Teflon tears per point separated in U and supported by a suture and finally sizing of the sutures.

Due to the oblong nature of the aneurysm, the size of the residual cavity and the position of the mitral abutments, in the two patients who had an associated aneurysm of the LV, we opted for the linear resection technique with direct closure of Aneurysmal banks. The same technique was used for the closure of the ventriculotomy

**Related gesture:** In a patient, a coronary bypass was performed on the right coronary artery.

**CPB:** The mean duration of CPB and aortic clamping was  $176 \pm 57.43$ min (116-230) and  $93 \pm 15.51$ min (84-114), respectively.

The release of the CPB took place in the 5 patients under drug, and IABP.

**Results:** The duration of the artificial ventilation lasted on average  $151, 8h \pm 95,90$  (11h-240h).

The mean duration in intensive care was  $228h \pm 139$  (11-384h).

**Mortality and surgical morbidity:** Immediate postoperative complications are summarized as follows:

Bleeding on average  $825ml \pm 522$  (350-1600ml) with 3 patients who required a blood transfusion.

One patient developed broncho-pneumopathy with well-evolved antibiotics, and one patient experienced a wake-up delay with agitation.

Operational mortality was defined by any death occurring during hospitalization or within 30 days postoperatively. Thus, two deaths were reported, an operating mortality of 40%. The cause of death was one for J2 by refractory cardiogenic shock and the other for ventricular tachycardia at day 16.



**Table 2 :** Summary of Post Operative Data

Settings	Number	or	Min-Max average
Duration of artificial ventilation	151,80±95,90 h		11 -240h
Stay in intensive care unit	228±139h		11 -384h
Bleeding	825 ml ± 522 ml		350 -1600 ml
Transfusion	(3)		60%
Refractory cardiogenic shock	(1)		20%
Broncho-pneumopathy	(1)		20%
Ventricular tachycardia	(1)		20 %
Use of drugs	(5)		100%
IABC	(5)		100 %
Operationnal mortality	(2)		40%

We followed the progress of the three survivors for 20 months (4-44 months). During this period we did not notice any significant events and the 3 patients were asymptomatic

#### IV. DISCUSSION:

Prior to the use of thrombolysis and percutaneous coronary intervention (PCI), the incidence of VSR after AMI was as high as 1-3% [1-5]. After reperfusion therapies became the standard of practice in the treatment of AMI, the incidence of VSR decreased to 0.17-0.31% [6]. However, despite the improvements in early diagnosis and treatment of both AMI and VSR, the mortality rate from VSR remains extremely high ranging from 45-80% [7].

Predictive factors for this complication have been reported in the literature (Table 1). As the advanced age; related to cardiac senescence and loss of myocardial self-protection ability [3].

In our patients, the mean age was 61.4 years ± 4.15 with extremes from 56 years to 63 years, but their physiological age did more because exact dates of birth were unknown.

Concerning the feminine sex, up to now the mechanism explaining this female predominance

remains unknown, a hypothesis has been proposed, based on the concept of having a collagen structure more susceptible to rupture [3]. All the patients were male, this can be explained because it is a population of mainly male military personnel.

The absence of a history of angina or myocardial infarction [2, 4], explaining the non-development of collateral circulation, thus promoting, Especially with complete occlusion of the artery responsible [2, 3], The creation of extensive transmural myocardial necrosis exposing the septal rupture.

This is the case for patients in our series, all of whom had a history of recent AMI (less than one month old).

**Table 3:** The Predictive Factors of Septal Rupture after AMI Found in the Literature

GUSTO-I	STROCK	Anna et all
Advanced age	Advanced age	Advanced age > 70 years old
Female sex	Female sex	Female sex
Anterior infarction	Inaugural infarction	Anterior infarction
No smoking	Tight stenosis TIMI 0/1	Tight monetrocular lesion
		Low Body Mass Index
		Left ventricular hypertrophy

In GUSTO-I [1], there was a linear relationship between systolic and diastolic pressures at the time of recruitment, and the incidence of septal rupture. The positive correlation (increased incidence of septal rupture with elevation of blood pressure above 130/75 mmhg) reflects the association between arterial hypertension and septal rupture. This is the case of patients in our series who were all hypertensive.

It has also been found that smoking is a protective factor against this complication.



A higher frequency was noted with anterior location of MI[1, 3]. All of our patients had a history of recent MI (less than one month old).

Clinically, septal rupture is most often manifested by sudden hemodynamic deterioration, accompanied by increased chest pain, dyspnea, jugular vein turgor and cardiogenic shock on predominantly right biventricular failure Of the course of MI.

We note the appearance of a systolic murmur over the precordium in 50% of the cases.

In our series, all patients had cardiogenic shock, dyspnea, chest pain, and systolic murmur over the precordium.

Usually, the diagnosis is made by a prompt transthoracic echocardiogram identifying drop-out of the ventricular septum in the 2D image and demonstration of flow across the septum using colour Doppler. Evidence of right-ventricular dilation and pulmonary hypertension are also important clues to the diagnosis. The remaining portions of the left ventricle are often hyperdynamic unless there is a large territory of infarction, or previous ischaemic insults have led to compromised function. Colour Doppler evaluation can also be useful to assess the anatomical size of the defect. When the patient has poor acoustic windows due to mechanical ventilation or body habitus, a TEE should be considered.

On the coronary plane, it is a mono-truncular lesion.

This is the case in our series where 4 patients (80%) were mono-truncular versus 1 patient (20%) who was bi-truncular.

Initial management aims at urgent hemodynamic stabilization of the patient, with conditioning (Peripheral venous pathway, bladder catheter, monitoring), pharmacological support comprising vasodilators, inotropes and diuretics.

IABP is set up rapidly to help decrease post-load, decrease myocardial oxygen consumption and improve coronary perfusion. [7-8]

Medical attempts to stabilize patients' condition are only adjuvants, as most patients require surgery.

The mortality rate in patients with septal rupture who are treated conservatively without surgical closure is approximately 24% in the first 24 hours, and 46% to one week, and 67 to 82% in two months.

Lemery et al reported a 30-day survival rate of 24% in medically treated patients, compared with a rate of 47% in those treated surgically.

Indeed, the surgical intervention of VSR reduces mortality by almost 50% compared to medical treatment. [9]

The only question that remains is the optimal timing of the intervention. However, in view of the improvement in surgical techniques, in particular the possibility of correction in friable tissues, septal rupture occurred earlier in patients with haemodynamic instability or even cardiogenic shock.

This is the case of all our patients who were operated early, given their unstable hemodynamic state.

In the majority of cases, the risk of surgery for urgent repair is accepted given the prognosis of progression without surgery. [10]

The operative mortality remains high and varies according to the authors from 11 to 35% [9;10]

The most important risk factors for mortality are the presence of preoperative cardiogenic shock, posterior location of rupture and right ventricular insufficiency resulting from an extension of right ventricular infarction.

In our series, two deaths were recorded, corresponding to an operative mortality of 40%, which is almost similar to the data in the literature.

The cause of death was for one, a cardiogenic shock refractory at day 2, and the other, a ventricular tachycardia at day 16.

#### **Late results:**

After the post-operative period, the long-term results are favorable.

Patients' survival at 5 years was 88%. The majority of these patients are a- or paucisymptomatic.

Associated revascularization during surgery appears to increase long-term survival. [10]

In our series, follow-up was of interest to 3 patients, as two patients died during hospitalization and lasted on average 20 months (4-44 months).

During this period we did not notice any significant events and the 3 patients were asymptomatic, which is consistent with the data from the literature.



## V. CONCLUSION:

Mechanical complications of myocardial infarction have become rare with the advent of a more invasive and early coronary reperfusion strategy; however, the prognosis of these complications remains bleak. They remain the consequence of a late reperfusion. This highlights the need to continue public information campaigns on the urgency of chest pain on the one hand, and on the other to continue our efforts to reduce reperfusion time in acute infarcts. Mechanical complications of infarction must always remain in the mind of the clinician against a patient presenting clinical and haemodynamic deterioration in the course of a myocardial infarction.

A good clinical knowledge of these complications often helps to identify them early and to take appropriate diagnostic and therapeutic measures as soon as possible. The echocardiography makes it possible to specify the type of complication, its importance and to orient the therapeutic strategy which is most often surgical. The mortality and morbidity after surgical correction of septal rupture after infarction remain severe. However, given the severity and the evolutionary nature of these ruptures, a rapid surgical correction seems justified.

## REFERENCES

1. Assessment of the safety and efficacy of a new treatment strategy with percutaneous coronary intervention (ASSENT-4 PCI) investigators. Primary versus tenecteplase-facilitated percutaneous coronary intervention in patients with ST-segment elevation acute myocardial infarction (ASSENT-4 PCI): Randomised trial. *Lancet* 2006;367:569-78.
2. Skehan JD, Carey C, Norrell MS, et al. Patterns of coronary artery disease in post-infarction ventricular septal rupture. *Br Heart J* 1989;62:268-72. [Medline]
3. Crenshaw BS, Granger CB, Birnbaum Y, et al. Risk factors, angiographic patterns, and outcomes in patients with ventricular septal defect complicating acute myocardial infarction. GUSTO-I trial investigators. *Circulation* 2000;101:27-32. [Medline]
4. Moreno R, Lopez-Sendon J, Garcia E, et al. Primary angioplasty reduces the risk of left ventricular free wall rupture compared with thrombolysis in patients with acute myocardial infarction. *J Am Coll Cardiol* 2002;39:598-603. [Medline]
5. Maltais S, Ibrahim R, Basmadjian AJ, et al. Postinfarction ventricular septal defects: Towards a new treatment algorithm? *Ann Thorac Surg* 2009;87:687-92. [Medline]
6. Birnbaum Y, Fishbein MC, Blanche C, Siegel RJ. Ventricular septal rupture after acute myocardial infarction. *N Engl J Med* 2002;347:1426-32.
7. Daggett WM, Burwell LR, Lawson DW, Austen WG. Resection of acute ventricular aneurysm and ruptured interventricular septum after myocardial infarction. *N Engl J Med* 1970;283:1507-12.
8. Lee W, Cardon L, Slodki S. Perforation of the interventricular septum. *Arch Intern Med* 1962;109:135
9. Kitamura S, Mendez A, Kay J. Ventricular septal defect following myocardial infarction. *J Thorac Cardiovasc Surg* 1971;61:186-99.
10. Hutchins G. Rupture of the interventricular septum complicating myocardial infarction: pathologic analysis of ten patients with clinically diagnosed perforations. *Am Heart J* 1979;97:165-70.